

Incidence of Hookworm Infection Related Anemia in Children in a Teaching Hospital in Telangana.

Indu Kapur¹, Ashwini Saminder Waghmare², C. Mallikarjuna Reddy³, M. Hima Bindu².

¹Professor, Department of Microbiology, Mallareddy Institute of Medical Sciences, Qutbullapur, Hyderabad, India

²Assistant Professor, Department of Microbiology, Mallareddy Institute of Medical Sciences, Qutbullapur, Hyderabad, India

³Assistant Professor³, Department of Microbiology, Mallareddy Medical College for Women, Hyderabad, India.

ABSTRACT

Background: *Ancylostoma duodenale* and *Necator americanus* are the blood sucking nematodes commonly called hookworms. They cause mild to severe anemia in patients especially children. The most common cause for hookworm infection is unhygienic conditions of the surroundings. **Methods:** 780 stool samples were collected from the children in wards, ICUs and schools. All the stool samples were subjected to wet mount by iodine and saline. They were also subjected to concentration technique by formalin ethyl acetate solution. Complete Blood Picture, estimation of Hemoglobin was done for all children for anemia and eosinophil testing. **Results:** 10.1% of the stool samples were positive for hookworms with 43 boys and 36 girls. 79.1% of the males and 88.3% of females were anemic with overall percentage being. Most of the children were from poor background with unhygienic conditions. **Conclusion:** Since most children belonged to poor background with unhygienic conditions, health education, improvement in sanitation, and mass treatment in affected areas can be tried.

Keywords: Concentration methods, Hookworm, anemia, Unhygienic conditions

INTRODUCTION

Hook worms are parasitic blood feeding nematodes, more commonly *Ancylostoma duodenale* and *Necator americanus*. These worms live in the small intestine of their host, which may be a bird or a mammal such as a dog, cat, or human.^[1] Hookworms are transmitted when hookworm eggs excreted in human faeces and incubated in appropriate soil conditions, hatched into larvae and enter a human host through aberrations in the skin. In contrast to *N. americanus*, *A. duodenale* can infect humans by the oral as well as the percutaneous route and may undergo arrested development in human organ systems in its larval stage.^[2]

Today, hookworm infection is among the most important tropical diseases in humans,^[2] the greatest number of hookworm cases occur in Asia, followed by sub-Saharan Africa.^[3] They are prevalent mostly in preschool and school-age children as well as in pregnant women.^[4,5]

576-740 million individuals are estimated to be suffering from hookworm infestation of which 80 million are severely infected. Over half of the infections are from Asia and the Pacific regions.^[6]

They cause intestinal blood loss, anemia and protein malnutrition especially in children in developing countries or under developed countries where hookworms are also known to cause stunted growth, low physical fitness and impaired intellectual and cognitive development.^[3,4] Additionally, helminthic infections have the capacity to reduce the host immune response to vaccines as well as to environmental and parasitic antigens.^[6-8] The consequences of such hypo-responsiveness may explain changes in host susceptibility to commonly encountered pathogens, or other antigens.^[9-14]

Dogs and cats act as natural reservoirs for hookworm transmission to humans. Hookworm infection is generally considered to be asymptomatic but it is an extremely dangerous infection because its damage is "silent and insidious." That is because although the worms suck enormous amounts of blood from the mucosal layers of the gut, the blood loss is seldom visible in the stools.^[15-17] The patient remains asymptomatic till he develops anemia. This blood loss is the most outstanding feature of hookworm infection.^[18,19]

MATERIALS AND METHODS

This study was conducted at Malla Reddy Institute of Medical Sciences over period of 2 years from June 2013 to May 2015. 780 stool samples of children between 5 years to 15 years were collected from the pediatric wards of Malla Reddy hospital and by camps conducted in schools by our hospital around Suraram village.

Name & Address of Corresponding Author

Dr. C. Mallikarjuna Reddy,
Assistant professor,
Dept of Microbiology
Mallareddy Medical College for women,
Hyderabad, India.
E mail: cpmreddy@gmail.com

All the stool samples were properly labelled and subjected to saline and iodine mounts. Approximately 5 g of stool was taken and subjected to concentration by formalin ethyl acetate technique. 10% formalin was added to the stool sample and mixed well. 5ml of the fecal suspension was strained through wetted cheese cloth kept over a disposable funnel in to 15ml conical centrifuge tube. 0.85% saline was added to tube to fill it up. The tubes were centrifuged at 1000rpm for 10 mins. Sediment was removed and 10ml of 10% formalin was added to the deposit and mixed well. 4 ml ethyl acetate was added and shaken well and centrifuged once again at 1000rpm for 10 mins. The sediment was removed and few drops of 10% formalin was added to the deposit. Wet mount was made from this suspension and seen under the microscope. The complete blood picture of all the patients was taken to check for anemia and eosinophil count. Hb estimation with cyan-

methemoglobin method was performed for all patients.

RESULTS

Of the 780 stool samples, 79(10.1%) of them were positive for *Ancylostoma duodenale* [Figure 1]. Most of the positivity was concentrated among schools which had comparatively unhygienic surroundings and children from poor background. Of the 79 positive samples, 43 (54.4%) were boys and 36 were girls (45.6%) [Figure 2].

66 (83.5%) of 79 children were anemic, some very severe. Amongst them, 43 were boys and 36 were girls. 34 of the 43 boys and (79.1%) 32 of the 36 girls (88.9%) were anemic. Elevated eosinophil counts were observed in 63.3% of the total cases [Table 1].

Table 1: Presence of anemia and eosinophilia among patients

Boys (N = 43)		Girls (N = 36)	
Anemic	High Eosinophil Count	Anemic	High Eosinophil Count
34 (79.1%)	27 (62.8%)	32 (88.9%)	23 (63.9%)

DISCUSSION

Our results show the prevalence of Hookworm to be 10.1%, which is consistent with other studies. Vittaya Jiraananku et al in Thailand found the prevalence to be 10.2%,^[6] while a study from Vellore found 22.8 per cent of all stool samples positive for hookworm.^[20] Another similar study by Deepti et al reported a prevalence of 7.8%.^[8]

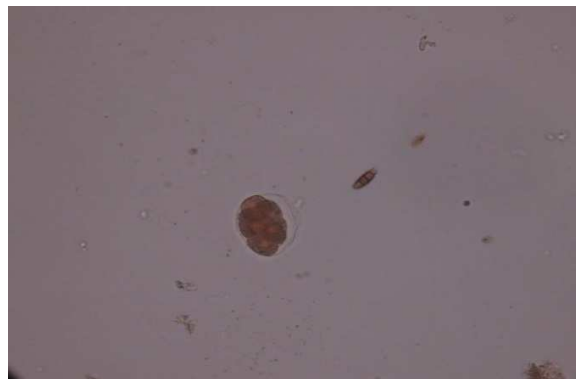


Figure 1: Stool sample positive for *Ancylostoma duodenale*.

Anemia was the most common complication among the children. Our study showed a prevalence of 83.5% of anemic cases among the hookworm infected children. More percentage of girls were anemic than the boys. The overall percentage of

anemic children with hookworm infestation in a similar study in Kenya coast was 76.3% and the anemic rate was around 80%.^[21,22] In another study in Zanzibar, 73% of the children with hookworm infection were anemic.^[23]



Figure 2: Gender wise distribution of *Ankylostoma* among children

It is said that the degree of iron deficiency anemia depends on the number of adult worms inhabiting the gut, the duration of infection, the iron storage and intake of the infected individual.^[24-27] But since we had not done a quantitative test or culture by Harada Mori technique, we could not establish this fact.

Helminthic infection may occur in community in clusters or may be isolated. The presence of infections in clusters can be mainly attributed to the fact that most parents in the category were

uneducated and slum dwellers. The hygiene in these schools was not properly maintained. No proper sanitation at the homes can also be a contributing factor. The same was noted by Deepti et al in their study in Vellore^[8] and by Alemu et al in Ethiopia.^[9] This fact of clustering in society can be a problem in treatment as the patients with heavy infection are likely to re-infect the community. All though there have been initiatives of mass administrations of anti-helminthic drugs in some states like in Vellore, a change in the hygiene, behavioral and social environments also need to be improved. Health education to the patients and relatives, importance of hygiene by the individual as well as the community is of utmost importance to keep this infection in check. It has been observed that mass treatment with a single dose of albendazole will eliminate a modest proportion of hookworms. . Mass treatment needs to balance feasibility and efficacy and impact on health outcomes. A 3-day regimen is unlikely to have high compliance, and a change in the regimen is therefore unlikely to happen in the foreseeable future.^[27]

CONCLUSION

Hookworms are notorious in being asymptomatic while causing severe blood loss from the patient and making them anemic. This is more prevalent among children and pregnant women. It easily spreads among closed communities, schools etc. Mass treatment of these infections are known to be quite effective in bringing down the numbers of the helminthes. But to know the prevalence of these infections, more such studies must be performed to quantify the number of helminthes in an area to effectively treat it. Health education, improvement of hygienic conditions, cleans toilets etc should be made available to the society.

REFERENCES

1. Hotez PJ, Bethony J, Bottazzi ME, Brooker S, Buss P Hookworm: The Great Infection of Mankind" PLoS Med. 2005;2(3):67.
2. Bethony J, Brooker S, Albonico M, Geiger SM, Loukas A, Diemert D, Soil-transmitted helminth infections: ascariasis, trichuriasis, and hookworm. Lancet. 2006;367:1521-32.
3. Noelle P, Elizabeth Y. Hookworm: Ancylostoma duodenale and Necator americanus: Lancet. 2008;370:1821-36.
4. Inpankaew T, Schär F, Dalsgaard A, Khieu V, Chimnoi W, Chhoun C. High prevalence of Ancylostoma ceylanicum hookworm infections in humans. Emerg Infect Dis. 2014; 20:65-72.
5. Stoll NR On endemic hookworm, where do we stand today? Exp Parasitol,1962;12:241-52.
6. Vittaya J, Wongwarit A, Mungthin M, Khositnithikul R, Ram R. Incidence and Risk Factors of Hookworm Infection in a Rural Community of Central Thailand Am J Trop Med Hyg.2011;84(4):594-8.
7. Kang G, Mathew MS, Rajan DP, Daniel JD, Mathan MM, Mathan VI, et al. Prevalence of intestinal parasites in rural southern Indians. Trop Med Int Health 1998;3:70-5.
8. Kattula D, Sarkar R, Swarna R, Ajjampur, Shantidani M, Levecke B. Prevalence & risk factors for soil transmitted helminth infection among school children in south India. Indian J Med Res ,2014;139:76-82.
9. Alemu A, Atnafu A, Addis Z, Shiferaw Y, Teklu T, Mathewos B, et al. Soil transmitted helminths and Schistosoma mansoni infections among school children in Zarima town, northwest Ethiopia. BMC Infect Dis 2011;11:189.
10. Albonico M, Stoltzfus RJ, Savioli L, Tielsch JM, Chwaya HM, Ercole E. Epidemiological evidence for a differential effect of hookworm species, Ancylostoma duodenale or Necator americanus, on iron status of children. International Journal of Epidemiology 1998;27:530-7.
11. Trape Jp. Rapid evaluation of malaria parasite density and standardization of thick smear examination for epidemiological investigations. Trans R Soc Trop Med Hyg 1985;79:181-4.
12. Johnson-Spear MA, Yip R. Hemoglobin difference between black and white women with comparable iron status: justification for race-specific anemia criteria. Am J Clin Nutr 1994;60:117-21
13. Gilles HM. Selective primary health care: Strategies for control of disease in the developing world Am J Clin Nutr 1998;65:127-31.
14. Pawlowski ZS, Schad GA, Stott GJ. Hookworm Infection and Anaemia: Approaches to Prevention and Control. Geneva: World Health Organization, 1991.
15. Miller TA. Hookworm infection in man. Adv Parasitol 1978;17:315-84
16. Schad GA. Presidential address. Hooked on hookworm: 25 years of attachment. J Parasitol 1991;77:177-86.
17. Schad GA, Chowdhury AB, Dean CG, Kochar VK, Nawalinski TA, Thomas J, et al Arrested development in human hookworm infections: an adaptation to a seasonally unfavorable external environment Science 1973;180:502-04.
18. Prociw P, Croese J. Human enteric infection with Ancylostoma caninum: hookworms reappraised in the light of a "new" zoonosis. Acta Trop 1996;62:23-44.
19. De Silva NR, Brooker S, Hotez PJ, Montresor A, Engels D, Savioli L. Soil-transmitted helminth infections: updating the global picture. Trends Parasitol 2003;19:547-51.
20. Albonico M, Allen H, Chitsulo L, Engels D, Gabrielli AF, Savioli L. Controlling soil-transmitted helminthiasis in pre-school-age children through preventive chemotherapy. PLoS Negl. Trop. Dis. 2008;2:126.
21. Mbuu JV, Ntonifor NH, Ojong J. The epidemiology of soiltransmitted helminth and protozoan infections in southwest Cameroon. J. Helminthol.2012;86:30-7.
22. Yazdanbakhsh M, Kreamsner PG, Rvan R. Allergy, parasites, and the hygiene hypothesis. Science 2002;296:490-4.
23. Esen M, Mordmüller B, de Salazar PM, Adegnika AA, Agnandji ST, Schaumburg F et al. Reduced antibody responses against Plasmodium falciparum vaccine

- candidate antigens in the presence of *Trichuris trichiura*. *Vaccine*,2012;30:7621–7.
24. Van Riet E, Adegnika AA, Retra K, Vieira R, Tielens AG, Lell B, et al. Cellular and humoral responses to influenza in Gabonese children living in rural and semi-urban areas. *J. Infect. Dis.*,2007;196:1671–8.
 25. Van den Biggelaar AH, Rodrigues LC, van Ree R, van der Zee JS, Hoeksma-Kruize YC, Souverijn JH M. et al. Long-term treatment of intestinal helminths increases mite skin-test reactivity in Gabonese schoolchildren. *J. Infect. Dis.* 2004;189:892–900.
 26. Maizels RM, Smith KA. Regulatory T cells in infection. *Adv. Immunol.* 2007;112:73–136.
 27. Adegnika AA, Zinsou JF, Issifou S, Ngoa UA, Kassa RF. Randomized, Controlled, Assessor-Blind Clinical Trial To

Assess the Efficacy of Single- versus Repeated-Dose Albendazole To Treat *Ascaris lumbricoides*, *Trichuris trichiura*, and Hookworm Infection, Antimicrobial Agents and Chemotherapy. 2014;58(5):2535–40.

How to cite this article: Kapur I, Waghmare AS, Reddy CM, Bindu MH. Incidence of Hookworm Infection Related Anemia in Children in a Teaching Hospital in Telangana. *Ann. Int. Med. Den. Res.* 2015;1(3):225-28.

Source of Support: Nil, **Conflict of Interest:** None declared