



Evaluation of various outcomes by histopathology among pleural effusion patients Running title: Pleural effusion

Jagpoornima Katoch¹, R. S.Negi^{2*}, S. K. Sharma³, Malay Sarkar⁴

¹Post graduate student, Department of Pulmonary Medicine, IGMC Shimla, Himachal Pradesh, India, Email: jpkatoch1@gmail.com, Orcid Id: 0000-0002-0411-6583

²Professor, Department of Pulmonary Medicine IGMC Shimla, Himachal Pradesh, India, Email: drrsnegi13@gmail.com, Orcid Id: 0000-0001-6438-9076. * Corresponding author

³Professor, Department of Pathology, IGMC Shimla, Himachal Pradesh, India, Email: sks995@gmail.com, Orcid Id: 0000-0001-9369-0722

⁴Professor, Department of Pulmonary Medicine IGMC Shimla, Himachal Pradesh, India, Email: drsarkarmalay23@rediffmail.com, Orcid Id: 0000-0002-9076-0948

Received: April 2021

Accepted: May 2021

Abstract

Background: The present study was conducted to evaluate various outcomes by histopathology among pleural effusion patients. **Methods:** 120 patients of pleural disease were screened for enrolment in the study. Smoking, previous history of anti-tubercular treatment etc. was recorded. All underwent medical thoracoscopy. Outcome was recorded. **Results:** 45(37.5%) were smokers, out of 79 males 39(49.36%) were smokers, out of which 20(25.3%) were heavy smokers, out of 41 females 6(14.6%) were smokers, 2(4.9%) out of 6 were heavy smokers. 101 (84.2%) had post-procedural hospital stay less than 5 days, whereas 19(15.8%) had post-procedural hospital stay was more than 5 days. The difference was non-significant ($p > 0.05$). 58 (48.3%) histopathological examination of pleural biopsy suggestive of granulomatous inflammation, 35(29.2%) suggestive of adenocarcinoma, 3(2.5%) suggestive of small cell carcinoma, 3(2.5%) suggestive of duct cell carcinoma, 2(1.7%) had spindle cells on histopathological examination of pleural biopsy. **Conclusion:** The medical diagnostic thoracoscopy along with histopathology has a relatively high diagnostic accuracy in patients of undiagnosed pleural effusion.

Key words: Pleural effusion, Granulomatous inflammation, Adenocarcinoma,

INTRODUCTION

Undiagnosed pleural effusions remain a diagnostic challenge for pulmonologists. In a patient with an undiagnosed pleural effusion, the first question to answer is whether the fluid is an exudate or transudate. Investigation of a pleural effusion evident on chest radiographs should follow a stepwise approach to diagnosis. Diagnosis begins with the clinical history, physical examination and chest radiography and is followed by thoracentesis when appropriate.

Recurrent and persistent pleural exudates are common in clinical practice, and in a large number of patients, thoracentesis and blind pleural biopsy procedures do not provide a definitive diagnosis. In the Western world, the majority of these exudates are malignant. Thoracoscopy today remains the gold standard technique in providing diagnosis and management in these cases.

Pleural effusion is a common presentation in clinical practice and can be caused by a large variety of malignant or benign cause [11]. Investigation of a pleural effusion evident on chest radiographs should follow a stepwise approach to diagnosis. Diagnosis begins with the clinical history, physical examination, and chest radiography and is followed by thoracentesis when appropriate.

In the past, rigid instruments were used for thoracoscopy that might have been considered relatively invasive in the setting of conscious sedation and local anesthesia. While using rigid thoracoscope, it was difficult to visualize posterior and mediastinal aspects of pleural

cavity without creating an extra port of entry especially when a lung was only partially collapsed. Moreover, most pulmonary physicians are not familiar with rigid thoracoscope and hence procedure was not much popular. The present study was conducted to evaluate various outcomes by histopathology among pleural effusion patients.

MATERIALS & METHODS

It is a cross-sectional hospital-based study conducted in the Department of Pulmonary Medicine and Department of Pathology IGMC, Shimla from July 2018 through June 2019. 120 patients of pleural disease were screened for enrolment in the study.

All included patients were subjected to written informed consent, detailed history was taken, regarding socio-demographic factors, age, gender, smoking, previous history of anti-tubercular treatment etc. was recorded. All underwent thoracoscopy.

Technique

The patient positioned in the lateral decubitus position, with normal lung in the dependent position and the affected side up with the arm above the head. Intravenous access secured through intravenous cannulation. All cases were performed using local anesthesia, Lidocaine 2% for local anesthesia of the skin, subcutaneous tissues, periosteum of ribs and parietal pleura. For sedation and analgesia, Midazolam and Diclofenac were given.

The patient's pulse and oxygen saturation by means of pulse oximetry were monitored. The

puncture site was marked with a skin marking pencil in the mid-axillary zone between the fourth and sixth intercostal spaces. Equipment required includes trocar and cannula with valve, thoracoscope, biopsy forceps, light sources, video system, aspiration system, chest tubes, drainage systems, water seal bags. The diameter of the rigid trocar used was 6 and 12.5 mm.

The single port entry technique for thoracoscopy was used. The patient skin prepared by disinfecting a large area to include from the sternum to the clavicle and across the axilla and down to the base of the thorax. The patient covered with a sterile sheet. For all cases, 1-2 cm skin incision was made with a scalpel, followed by blunt dissection of intercostal muscles until the reduction of resistance is felt and the parietal pleura reached. Then the rigid trocar which of size 6mm in inner diameter was introduced in a corkscrew motion until the sudden release of the resistance felt while holding the handle of trocar firmly in the palm of the hand, as extended index finger, for safety sake, limit the depth of insertion. The inner part of the trocar then withdrawn slowly and carefully. Pleura

fluid aspiration was done. The thoracoscope was introduced inside the trocar.

The pleural space then inspected. The procedure went through the following phases: (1) careful aspiration of the pleural fluid; (2) dissection of adhesions preventing proper inspection of the pleural space if present (3) inspection of the pleural space using a direct viewing telescope and (4) multiple biopsy samples (usually 5-8) were obtained under direct vision from any abnormal areas in the parietal pleura with the biopsy forceps. The thoracoscope was removed followed by the removal of trocar and chest tube (24-32F) connected to an underwater seal was introduced through the same place. A post-procedure chest X-ray was done. All the thoracoscopy guided pleural biopsy specimens were sent for histopathological examination to the department of pathology. Biopsy specimens were stained with hematoxylin and eosin stain (H&E). In some cases where results were inconclusive, special staining was done. The chest tube was removed as soon as the lung was clinically and radiologically re-expanded with a minimal amount of pleural fluid drainage (<100 cc/24 h) and there was no air leak. Results were statistically analyzed

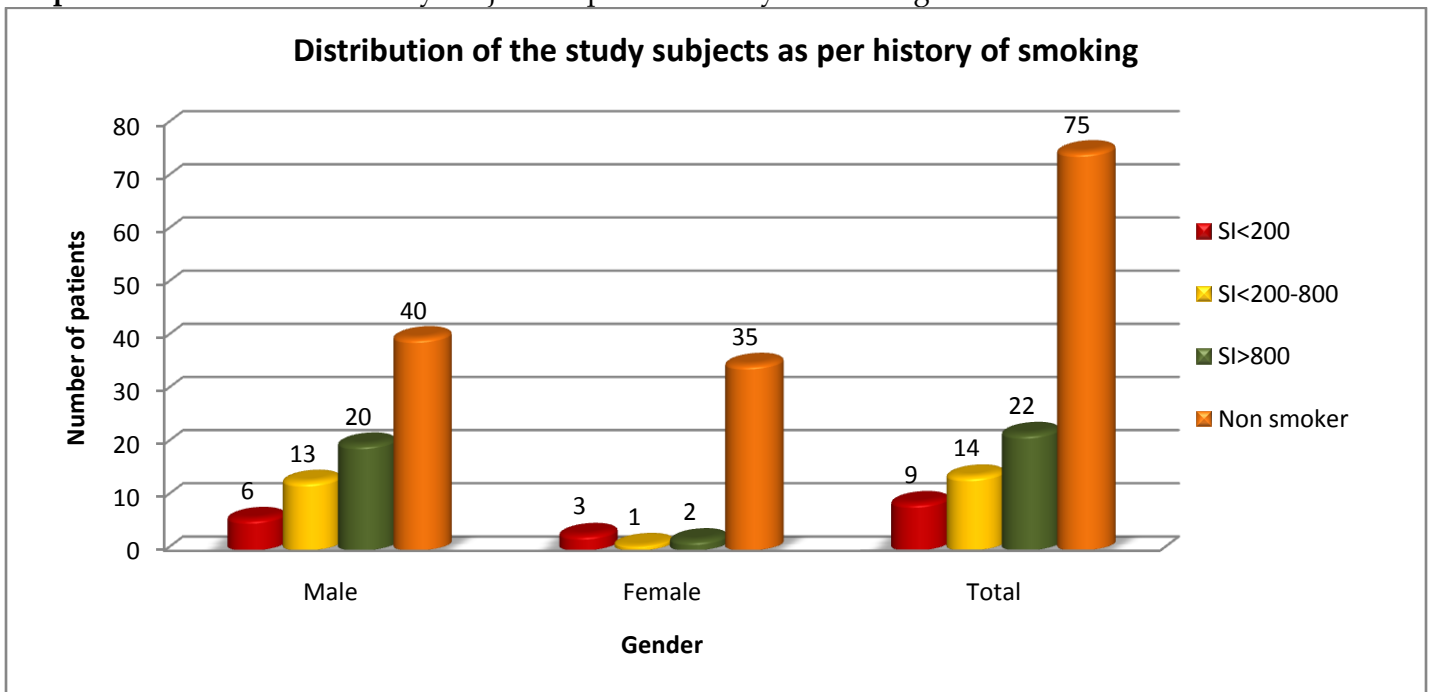
RESULTS

Table I: Distribution of the study subjects as per the history of Indoor pollution

Indoor pollution	Male		Female		Total		Male Vs Female	
	n	%	N	%	n	%	Chi-square value	P value
Present	24	30.4	10	24.4	34	28.3	0.477	0.490
Absent	55	69.6	31	75.6	86	71.7		
Total	79	100.0	41	100.0	120	100.0		
Chi-square value	12.165		10.756		22.533			
P value	<0.001 S		0.001 S		<0.001 S			

Table I shows that 34(28.3%) had history of indoor air pollution exposure in form of burning of biomass fuel, out of 79 males,24(30.4%) had indoor air pollution exposure whereas out of 41 females,10 females(24.4%) exposed to indoor air pollution. The difference was non- significant ($p > 0.05$).

Graph I:Distribution of the study subjects as per the history of smoking



Graph I shows that 45(37.5%) were smokers, out of 79 males 39(49.36%) were smokers, out of which 20(25.3%) were heavy smokers, out of 41 females 6(14.6%) were smokers,2(4.9%)out of 6 were heavy smokers.

Table II:Distribution of the study subjects as per length of stay

Length of stay	Male		Female		Total		Male Vs Female	
	n	%	n	%	N	%	Chi-square value	P value
<5days	68	86.1	33	80.5	101	84.2	0.632	0.426 NS
>5day	11	13.9	8	19.5	19	15.8		
Total	79	100.0	41	100.0	120	100.0		
Chi-square value	41.127		15.244		56.033			
P value	<0.001 S		<0.001 S		<0.001 S			

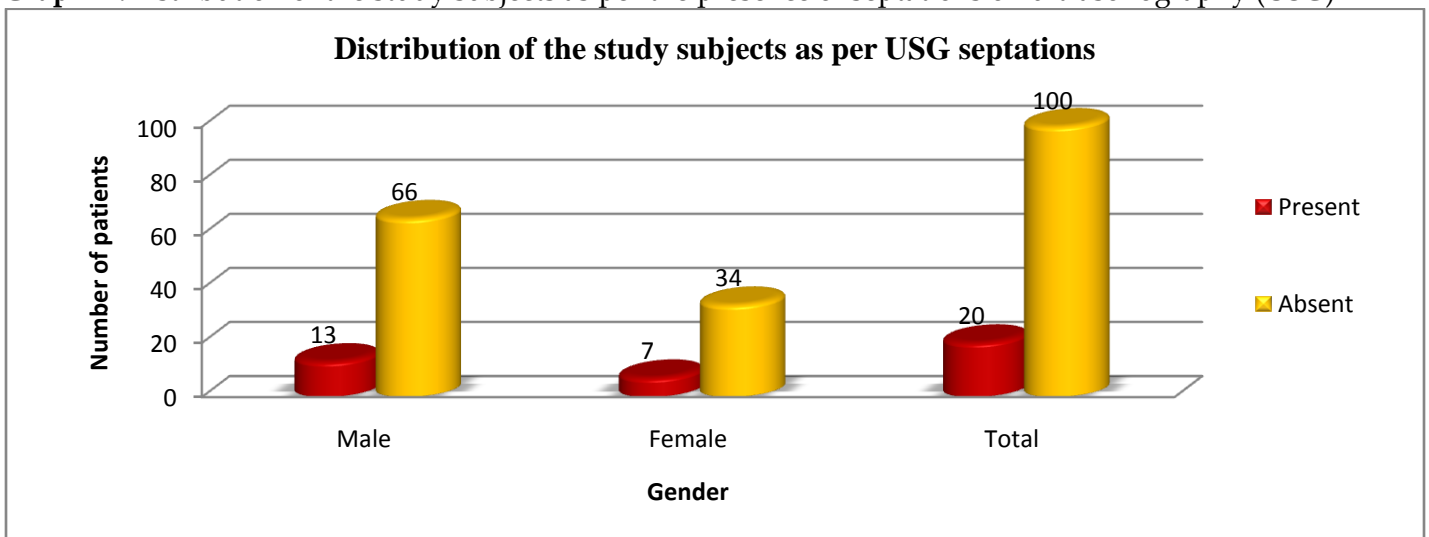
Table II shows that 101 (84.2%) had post- procedural hospital stay less than 5 days, whereas 19(15.8%)had post- procedural hospital stay was more than 5 days. The difference was non- significant ($p > 0.05$).

Table III:Distribution of the study subjects as per histological findings

Histological findings	Male		Female		Total		Male Vs Female	
	n	%	n	%	n	%	Chi-square value	P value
Granulomatous inflammation	38	48.1	20	48.8	58	48.3	3.368	0.643 NS
Adenocarcinoma	24	30.4	11	26.8	35	29.2		
Small cell carcinoma	3	3.8	0	0.0	3	2.5		
Duct cell carcinoma	1	1.3	2	4.9	3	2.5		
Spindle cells	1	1.3	1	2.4	2	1.7		
Others	12	15.2	7	17.1	19	15.8		
Total	79	100.0	41	100.0	120	100.0		
Chi-square value	58.785		29.122		87.917			
P value	<0.001 S		<0.001 S		<0.001 S			

Table III shows that 58 (48.3%) histopathological examination of pleural biopsy suggestive of granulomatous inflammation,35(29.2%) suggestive of adenocarcinoma,3(2.5%) suggestive of small cell carcinoma,3(2.5%)suggestive of duct cell carcinoma,2(1.7%) had spindle cells on histopathological examination of pleural biopsy.

Graph II:Distribution of the study subjects as per the presence of septations on ultrasonography (USG)



Graph II shows that 20(16.7%) had septations present on chest ultrasonography.Out of 79 males, 13(16.5%) had septations whereas out of 41 females 7(17.1%) had septations on chest ultrasonography.

DISCUSSION

In patients with suspected tuberculous pleurisy, thorascopicpleural biopsy under local anesthesia should be activelyperformed, because the technique has a high diagnostic rate and can be easily and safely performed.⁹The semi-rigid thorascopeachieves a diagnostic yield similarto that of the conventional rigid instrument despite thesmaller biopsy size. Both instruments remain valuable in theevaluation and management of pleural disease.^[10] The present study was conducted to evaluate various outcomes by histopathology among pleural effusion patients.

We found that 34 (28.3%) had history of indoor air pollution exposure in form of burning of biomass fuel, out of 79 males, 24(30.4%) had indoor air pollution exposure whereas out of 41 females, 10 females (24.4%) exposed to indoor air pollution. 45 (37.5%) were smokers, out of 79 males 39 (49.36%) were smokers, out of which 20 (25.3%) were heavy smokers, out of 41 females 6 (14.6%) were smokers, 2 (4.9%) out of 6 were heavy smokers. Blanc et al^[11] carried out a study to analyzed the diagnostic yield of medical thoracoscopy and its value in the management of the pleural disease. These 154 patients underwent medical thoracoscopy, of which 149 were diagnostic and 19 were for therapeutic assessment in malignant mesothelioma. Prior to thoracoscopy, at least one closed pleural biopsy had been performed in 120 of 149 cases, yielding a diagnosis in 96 cases. The results showed that in 43 of 96 cases, the results from medical thoracoscopy were discordant from those of closed pleural biopsy. In 66 cases of nonspecific inflammation

diagnosed by closed pleural biopsy, thoracoscopy revealed malignant mesothelioma in 16 cases, adenocarcinoma in 10 cases, other types of carcinoma in 3 cases, and pleural tuberculosis in 3 cases. In 12 cases of carcinoma diagnosed by closed pleural biopsy, thoracoscopy specified the histologic type in 7 cases. Overall, this retrospective study noted that medical thoracoscopy modified 43 of 96 of the prior CPB-based diagnoses (45%), with an overall diagnostic efficiency of 93%, and the procedure appeared to be relatively safe despite one thoracoscopy related death (0.6%). The major advantage of medical thoracoscopy is that it permits biopsy with direct visualization. Another advantage is that medical thoracoscopy can be performed by a pulmonologist under local or regional anesthesia.

We found that 101 (84.2%) had post-procedural hospital stay less than 5 days, whereas 19(15.8%)had post- procedural hospital stay was more than 5 days.58 (48.3%) histopathological examination of pleural biopsy suggestive of granulomatous inflammation,35(29.2%) suggestive of adenocarcinoma,3(2.5%) suggestive of small cell carcinoma,3(2.5%)suggestive of duct cell carcinoma,2(1.7%) had spindle cells on histopathological examination of pleural biopsy.Hansen et al^[12] carried medical thoracoscopy results and complications in 146 patients. The overall diagnostic sensitivity was 90.4%. The results demonstrated 62% with malignancy of the pleura, and 38% revealed benign pleural diseases, among them 2% with tuberculosis. The sensitivity for malignancy was found to be 88% and the specificity 96%. The most common primary lung cancer with

involvement of the pleura was adenocarcinoma (62%), and the most common metastatic tumor originated from the breast (28%). The sensitivity for tuberculosis was 100% and the specificity 100%. No mortality was found, and the morbidity was low at about 0.6% (empyema, pleuro-cutaneous fistula, transcutaneous growth of mesothelioma). The medical diagnostic thoracoscopy in local anesthesia is a simple low-cost investigation

REFERENCES

1. Guerin JC, Boutin C. Interventional medical thoracoscopy. *Rev Mal Respir*1999; 16:703-708
2. Almind M, Lange, Viskum K. Spontaneous pneumothorax: comparison of simple drainage, talc pleurodesis, and tetracycline pleurodesis, *Thorax* 1989; 44:627-630
3. Bresticker MA, Obs J, LoCicero J. Optimal pleurodesis: A comparison study. *Ann ThoracSurg*1989; 55:364-366
4. Tschopp JM, Brutsche M, Frey JG. Treatment of complicated spontaneous pneumothorax by simple talc pleurodesis under thoracoscopy and local anesthesia. *Thorax* 1997; 52:329-332.
5. Silen ML, Naunheim KS. Thoracoscopic approach to the management of empyema thoracis. Indications and results. *Chest SurgClinN Am*1996;6:491-499.
6. Marios E. Froudarakis *Respiration* 2008;75:4-13
7. Patil CB, Dixit R, Gupta N, Indushekhar V. Thoracoscopic evaluation of 129 cases having undiagnosed exudative pleural effusions. *Lung India* 2016;33:502-6.

with a relatively high diagnostic accuracy, no mortality and low morbidity.

The limitation of the study is small sample size.

CONCLUSION

The medical diagnostic thoracoscopy along with histopathology has a relatively high diagnostic accuracy in patients of undiagnosed pleural effusion.

8. Sabah A. Mohamed, MarwaM. Shaban. Diagnostic yield of medical thoracoscopy in diagnosis of exudative pleural effusion: One year prospective study. *Egyptian Journal of chest disease and tuberculosis*. 2014; 5-13.
9. R. Loddenkemper. Thoracoscopy - state of the art. *EurRespir J* 1998; 11: 213-221.
10. Prabhu V G, Narasimhan R. The role of pleuroscopy in undiagnosed exudative pleural effusion. *Lung India*. 2012 Apr-Jun; 29(2): 128-130.
11. Blanc FX, Atassi K, Bignon J, Housset B. Diagnostic value of medical thoracoscopy in pleural disease: 6 -year retrospective study *Chest*. 2002 May; 121(5):1677-83.
12. M.Hansen, Fourschou P, Clementsen P. Medical thoracoscopy, results and complications in 146 patients: a retrospective study. *Respiratory Medicine* 1998; 92,228-232.

Source of Support: Nil, Conflict of Interest: None declared