

Emissary Sphenoidal Foramen: Rare but not to ignore.

Ajit pal Singh¹, Jeewanjot Sekhon²

¹Professor, Dept. of Anatomy, Desh Bhagat Dental College & Hospital, Sri Muktsar Sahib, Punjab.

²Senior Lecturer, Dept. of Anatomy, Desh Bhagat Dental College & Hospital, Sri Muktsar Sahib, Punjab.

ABSTRACT

Background: Emissary sphenoidal foramen also named as foramen Vesalius is a rare opening found near the scaphoid fossa and located exteriorly on the base of skull, antero-medial to foramen ovale, spinosum and carotid canal whereas postero-medial to the foramen rotundum. **Methods:** A total 28 dry adult human skulls were observed & studied for the presence of emissary sphenoidal foramen (ESF) in the department of anatomy at Desh Bhagat Dental College & Hospital, Sri Muktsar Sahib, Punjab. Unilateral and bilateral presence of ESF were noted. **Results:** Total 56 sides of 28 skulls were studied and it was found that 08 ESF were observed on right side and 02 on left side with an incidence of 28.5% and 7.1% respectively. **Conclusion:** Present study highlights the incidence of ESF and describes its neuro-anatomic importance.

Keywords: Emissary Sphenoidal Foramen, Emissary Veins, Morphometry, Neuroanatomy

INTRODUCTION

Human skull has approximately 85 named foramina, canals and fissures through which various neurovascular structures pass and build communications between interior and exterior of the skull. Majority of the foramina has been observed on the base of skull i.e. incisive foramen, greater and lesser palatine foramen, vomero-vaginal canal, palatino-vaginal canal, foramen ovale, foramen spinosum, foramen lacerum, jugular foramen, carotid canal, foramen magnum, hypoglossal canal, condylar canal etc.^[1,2] Instead of these foramina there are some of the accessory openings which are also observed along with these and seem to highlight clinically important information. Emissary sphenoidal foramen (ESF) which is also named as “*Foramen Vesalius*” is one of the rare openings used to be observed near the scaphoid fossa and located exteriorly on the base of skull antero-medial to the foramen ovale, foramen spinosum and carotid canal whereas postero-medial from the foramen rotundum interiorly. Emissary sphenoidal foramen (ESF) transmits emissary vein which is valve less vessel and build communication between extra-cranial and intra-cranial veins. It has been also reported that nervulus sphenoidal lateralis (small nerve) may also accompany the emissary vein and enters the cavernous sinus. In 20% of the reported cases, presence of accessory meningeal artery has been found crossing ESF.

According to its presence unilaterally or bilaterally, Gray’s anatomy and Soames highlighted 40% of cases in which ESF exists on one or both sides of skulls. Because of extra and intra cranial communication path, emissary sphenoidal foramen became the cause for spread of infection in cavernous sinus but some time its position is misplaced with foramen ovale as the ESF is present very close to it during the treatment of trigeminal neuralgia and resulted into intracranial bleeding. Vesalius in his famous book *de humanicorporisfabrica* describes the foramen with uncommonly subjective language “*because one skull more elegant than the others, belonging to a man of middle age by far the most handsome I have ever seen displays this foramen*”.^[2-8] Present study has been conducted with a view to establish the incidence of emissary sphenoidal foramen and its clinical correlation since the literature related to the same is still lacking.

MATERIALS & METHODS

The present study was conducted in the department of Anatomy in Desh Bhagat Dental College & Hospital, Sri Muktsar Sahib (Punjab). A total 28 dry adult human skulls were observed & studied for the presence of emissary sphenoidal foramen (ESF). Skulls were washed properly with soft brush and foramen was confirmed by inserting a very thin ortho wire through each foramen. Unilateral and bilateral presence of ESF was also noted. The results were compared with the previous literature.

Name & Address of Corresponding Author

Dr. Ajit pal Singh
Professor, Dept. of Anatomy,
Desh Bhagat Dental College & Hospital, Sri Muktsar Sahib,
Punjab, (India)
E mail: doctoraps@gmail.com

RESULTS

A total of 28 human dry skulls were examined out of which 16 skulls had at least one emissary sphenoidal foramen, resulting in 57.1% overall incidence. There are 10 skulls having unilateral while 08 skulls had

bilateral presence of ESF resulting in incidence of 35.71% and 28.5% respectively. The total number of 56 sides of 28 skulls were studied and it was observed that 08 ESF were found on the right side and 02 on the left side with an incidence of 28.5% and 07.1% respectively [Table 1, Figure 1].

Table 1: Incidence of emissary sphenoidal foramen (ESF)

No. of Skulls Examined (N)	28
No. of skulls having ESF	16 (57.1%)
Unilateral incidence of ESF	10(35.71%)
Bilateral incidence of ESF	08 (28.5%)
Incidence of ESF on right side only	08 (28.5%)
Incidence of ESF on left side only	02 (07.1%)

DISCUSSION

Emissary veins build important links between the intra and extra cranial cavity. These are very minute veins which pass through the various foramina present in the skull i.e stylomastoid foramen, parietal foramen etc. Emissary Sphenoidal Foramen (ESF) is one such rare foramen located between the foramen rotundum and foramen ovale, carrying emissary vein also called as Vein of Vesalius. Embryologically, ESF usually shows its origin at the site of fusion between the membranous bone and medial cartilaginous ala temporalis.^[9]

In the present study the ESF exists in 57.1% of the skulls and thus shows increasing tendency as compared to rest of the studies under consideration

[Table 2]. Presence of ESF is more on right side (28.5%) as compared to left side (7.10%). According to Vesalius, emissary sphenoidal foramen is rarely seen unilaterally and even more rarely bilaterally.^[7] Gupta reported presence of this foramen 42.8% (2005) and 34% (2014), out of which 17.10% & 15% (2005) on right side and 2.85% & 19% (2014) on left side. According to study conducted by Rossi total incidence of ESF is 40.6% out of which 15.62% on right side and 11.25% on left side and 13.76% bilaterally. Nirmala and Hema reported the overall incidences of ESF 50% out of which 10% on right side and 16.67% on left side and 23.3% bilaterally. Embryological or developmental factors explained the variations in ESF.^[9,10]

Table 2: Comparison of present study with previous studies.

Author	No. of Skulls examined (N)	Total incidence	Incidence of ESF		Bilateral
			Unilateral Right side	Unilateral Left side	
Gupta et al.2005 ⁽⁵⁾	35	42.8%	17.10%	2.85%	22.85%
Rossi et al.2010 ⁽¹⁴⁾	80	40.6%	15.62%	11.25%	13.76%
Gupta et al.2014 ⁽¹³⁾	200	34%	15%	19%	14%
Nirmala & Hema,2014 ⁽¹⁵⁾	180	50%	10%	16.67%	23.3%
Present study , 2015	28	57.1%	28.5%	7.10%	28.5%

ESF plays a significant role during various neurosurgeries as the emissary veins that course through it has interlinks with pterygoid plexus and cavernous sinus.^[11] The surgical importance lies in the fact that the emissary veins passing through the ESF may convey the infected thrombus from the exterior of the skull to the interior of the cranial cavity.^[2] Thrombophlebitis or septic thrombosis may occur through dissemination by contiguity which is

caused by supportive processes at the orbit, paranasal sinuses or the upper half of face level, such as boils, sinusitis or otitis, and rarely dental infection. More commonly infection spreads to the contra-lateral cavernous sinus through the circular sinus.^[12]

The treatment of trigeminal neuralgia is done by trans-ovale approach rhizotomy associated with fluoroscopy and to guide a needle puncture to the trigeminal impression. One important aspect of this

treatment is the foramen ovale penetration and the needle is placed at the third branch of the trigeminal nerve, as the ESF is located quite close to the foramen ovale so chances of ESF puncture is very common.

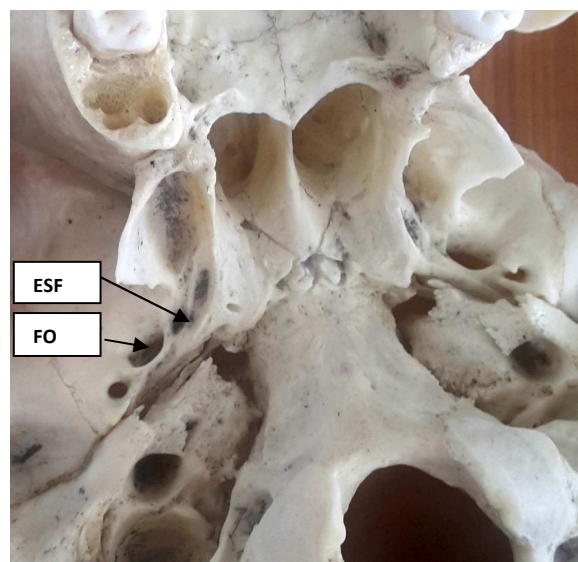


Figure 1: Inferior view of the base of skull showing the emissary sphenoidal foramen (ESF) located anterior and medial to the foramen ovale (FO) as indicated by arrows.

Anthropologists also acquire important information from the anatomical basis of ESF and later used in studying the racial and sex variations in the skull.^[13-15]

CONCLUSION

Although emissary sphenoidal foramen is not common and can be found rarely but it should not be ignored or taken as abnormal variation. Anatomical consideration of ESF with special reference to its neurovascular structures is very important for neurologists in performing various neurosurgeries.

REFERENCES

1. Gray H, Bannister LH, Berry M, William PL. Osteology. In Gray, H., Bannister LH and William PL. Gray's Anatomy.38th.London: Churchill Livingstone; 1995. pp 344.

2. Datta AK. Essentials of human anatomy (Head & Neck Part –II) 3rd edition reprint Kolkata: Current books international.jain; 2003. pp16.
3. Williams PL, Bannister IH, Martin MM et al. Gray's Anatomy.38th.London: Churchill Livingstone; 1995. pp 425-736.
4. Lang J. Clinical Anatomy of the head. Neurocranium Orbit and Craniocervical region. Springer-Verlag, Berhn.1883.
5. Gupta N, Ray B, Gosh S. Anatomic characteristic of foramen vaselius. Katmandu University Medical Journal. 2005; 3(2):155-158.
6. Soames RW. Skeletal system: sphenoid bone.In: William PL, chief editor.Gray's Anatomy.38th edition. London.Churchill Livingstone., 1995. p586.
7. Hast MH, Garrison DH.2000.Vesalius on variability of the human skull.Book 1 Chapter 5th of De Humancarpofabrica Chn Anat.2000;13:311-20.
8. Kodama K, Lnoue K, Nagashma M, Matsumura G, Watanabe S, Kodama G.Studies on the foramen Vesalius in the Japanese juvenile and adult skulls. Hokkaido IjgakaZasshi.1997;72(6), 667-674.
9. James TM, Presley R, Steel FL. The foramen ovale and sphenoidal angle in man. Anat Embryol (Berl).1980;160:93-104.
10. Nemzek WR, Brodie HA, Hecht ST, Chong BW, Babcock CJ, Seibert JA. MR, CT, and plain film imaging of the developing skull base in fetal specimens. American Journal of Neuroradiology. 2000; 21:1699-706.
11. Decker Gag, du Plesis DJ. McGregor's Synopsis of Surgical Anatomy. 12th edn. John Wright & Sons Ltd. Bristol. 1986. p 328-333.
12. Freire AR, Rossi AC, De Oliveira VCS, Prado FB, Caria PHF, Botacin PR. Emissary foramens of the human skull : Anatomical characteristics and its relations with clinical neuro surgery.Int J Morphol.2013;31(1);287-292.
13. Gupta N, Yadav A, Thomas RJ, Shrivastava A. Incidence of Foramen Vesalius in adult human north Indian crania. J Dent & Med.Sc.2014;13(5):34-38.
14. Rossi AC, Freire AR, Prado FB, Caria PHF and Botacin PR. Morphological characteristics of foramen of vasalius and its relationship with clinical implications. Journal of Morphological Science.2010; 27(1):26-29.
15. Nirmala D and Hema N. Study of emissary sphenoidal foramen and its clinical implications.J Evidence Based Med.&Healthcare.2014;1(4):175-179.

How to cite this article: Singh AP, Sekhon J. Emissary Sphenoidal Foramen: Rare but not to ignore. Ann. Int. Med. Den. Res. 2015;1(3):218-20.

Source of Support: Nil, **Conflict of Interest:** None declared