

Role of Induced Sputum, Bronchial Aspirate and Post Bronchoscopic Sputum in the Diagnosis of Sputum Smear Negative Pulmonary Tuberculosis.

Swetha Madas¹, Mallikarjuna Reddy C², Hima Bindu M³, Kumaraswamy koutam⁴.

¹Assistant Professor, Dept of Pulmonary Medicine, Mallareddy Institute of Medical Sciences, Hyderabad, India.

²Assistant Professor, Dept of Microbiology, Mallareddy Medical College for Women, Hyderabad, India

³Assistant Professor, Dept of Microbiology, Mallareddy Institute of Medical Sciences, Hyderabad, India.

⁴Senior Resident, Dept of Pulmonary Medicine, Mallareddy Institute of Medical Science, Hyderabad, India.

ABSTRACT

Background: The diagnosis of Pulmonary Tuberculosis is largely dependent of the positive result of the sputum smear by ZN staining. But in many cases, although active tuberculosis is present, due to many reasons, sputum smear may yield a negative result. With a late culture result, no reliable serological test available to enable an early diagnosis, role of induced sputum and bronchoscopy has been tried with excellent results. **Methods:** 50 fresh smear negative cases between the ages of 16-65 years, clinically and radiologically suspected of Pulmonary Tuberculosis were subjected to induced sputum and bronchoscopy after detailed history and thorough clinical examination as done. Clinical symptoms were noted, 2 sputum smears (spot and early morning) and chest x-rays were taken for all patients. **Results:** Males between 24 – 44 years were seen to be predominant patients. The most common symptom appeared to be cough in 80% followed by fever in 60% of the cases. 76% of patients had unilateral lesions and 24% with bilateral lesions. 84% of the sputum negative patents were identified as active tuberculosis cases. **Conclusion:** Induced sputum and fiber optic bronchoscopy with bronchial aspirate and post bronchoscopic sputum can provide excellent material for diagnosis of suspected cases of Pulmonary Tuberculosis in whom smears of expectorated sputum do not reveal mycobacteria. There is minimum patient discomfort, reduced complications and relatively good yield which makes these procedures justifiable in the diagnosis of fresh smear negative pulmonary tuberculosis.

Key Words: Bronchial wash, bronchoscopy, induced sputum, Smear negative.

INTRODUCTION

Tuberculosis is a widespread, highly infectious disease, fatal in many cases and caused by various stains of Mycobacteria, usually *M. tuberculosis*.^[1] Tuberculosis typically attacks the lungs, but can also affect other parts of the body.^[2] General signs and symptoms include fever, chills, night sweats, loss of appetite, weight loss, and fatigue.^[3]

It is estimated that about one-thirds of the world's population is infected with Tuberculosis^[4] and new infections occur in about 1% of the population each year.^[5] Though India is the second-most populous country in the world, India has more new TB cases annually than any other country. In 2009, out of the estimated global annual incidence of 9.4 million TB cases, 2 million were estimated to have occurred in India, thus contributing to a fifth of the global burden of TB. It is estimated that about 40% of Indian population is infected with TB bacillus.^[6]

The initial diagnostic approach to suspected cases of Pulmonary Tuberculosis is to demonstrate Mycobacterium tuberculosis in stained smears of expectorated sputum. In most of the tuberculosis centers, even after meticulous search, the positive yield from sputum is only around 16 to 50% with a large portion of samples remaining negative, in spite of clinical profile and radiological lesions being consistent with diagnosis of Pulmonary Tuberculosis. The difficulty is further compounded by the fact that culture of Mycobacterium tuberculosis requires 6-8 wks, rapid tests are costly and not available in all centers, a reliable serological test is not yet available.^[7] Antitubercular treatment is frequently started empirically leading many a times to risk of drug toxicity. In such a situation, role of induced sputum and bronchoscopy has been tried for rapid diagnosis of tuberculosis in smear negative cases.^[8] Induced sputum, flexible fiber optic bronchoscopy (FOB) with bronchial aspirate and post bronchoscopic sputum have an extensive diagnostic potential in Pulmonary Tuberculosis. The fiber optic bronchoscopy with bronchial aspirate analysis and post bronchoscopic sputum for AFB has significant role in establishing the diagnosis in those cases where the extensive search for AFB in expectorated sputum has repeatedly failed or those cases where sputum

Name & Address of Corresponding Author

C. Mallikarjuna Reddy,
Assistant Professor, Department of Microbiology
Mallareddy Medical College for Women
Suraram, Hyderabad.
Email id: cpmreddy@gmail.com

Madas et al; Diagnosis of Sputum Smear Negative Pulmonary Tuberculosis

expectoration is absent or the sputum induction has failed.^[9, 10]

Hence, this work was conducted to study the yield of Acid Fast Bacilli in Induced sputum, Bronchial aspirate and Post-bronchoscopic sputum and establish their importance in the diagnosis of Pulmonary Tuberculosis in sputum smear negative cases.

MATERIALS AND METHODS

The present study was conducted in the Department of Pulmonary Medicine, Mallareddy Institute of Medical Sciences, Jeedimetla, Hyderabad during the period Dec 2012 - 2014. 50 fresh smear negative cases between the ages of 16-65 years, clinically and radiologically suspected of Pulmonary Tuberculosis were selected in this study. Detailed history of each patient was recorded. Thorough clinical examination was done and patients having Cough with expectoration of more than 2 weeks, Fever, Loss of appetite, Hemoptysis, etc were included in the study. Two sputum smears for acid fast bacilli, Spot, early morning were taken from each patient. Chest X rays were taken for all patients and looked for bilateral involvement, infiltrations in the upper zones and with cavitations and satellite lesions, fibrosis etc.

All sputum samples were sent for microscopic examination by Zeihl Nelson's Staining (ZN Stain) for establishment of smear negative cases after which the patient was sent for induced sputum. Induced sputum was collected by nebulisation using 3% hypertonic saline before the patient was subjected to bronchoscopy. After taking informed consent from the patient, they were premedicated 30-45 minutes prior to Bronchoscopy with Inj. Atropine (0.6 mg i.v). Bronchoscopy was carried out under local anesthesia, 4% lignocaine was sprayed to both the

nostrils and mouth with a syringe. If bilateral lesions were present bronchoscope was maneuvered up to segmental bronchi and observed for mucosal irregularity, ulcerations, granulations and any growth. Bronchial aspirate was collected wherever secretions were noted. If required, 0.9% isotonic saline at room temperature was instilled through the internal channel of FOB and aspirated into a trap connected to suction tubing. After the procedure, the development of pneumothorax, hemorrhage, infection and cardiac arrhythmias were looked for 24-48 hours. The first sputum sample after bronchoscopy (post bronchoscopic sputum) was collected and sent for analysis along with bronchial aspirate.

RESULTS

The clinical data for all the 50 patients were documented. Of the 50 patients studied, 37 were males and 13 were females. The maximum patients were seen in the age group between 25 -35 in both males and females [Figure 1].

The youngest patient was aged 18 years and oldest 60 years. Mean age of the study population was 35.58 years. The mean age of males was 37.24 years and that of females was 30.86 years.

The most common symptom was cough for over 2 weeks in 80% of patients, followed by fever in 60% [Figure 2].

Thirty eight (76%) patients had unilateral lesions [Figure 3] and twelve (24%) had bilateral lesions. [Figure 4] Twenty three (46%) had cavitary lesions, and twenty seven patients (54%) had infiltration without cavitations [Table 1]. Twenty nine patients (58%) had minimal lesion, sixteen (32%) had moderately advanced lesion and five (10%) patients had far advanced lesion on X-ray chest.

Table 1: Radiological manifestations

Radiological Manifestations		Number	Percentage	
Site of Lesion	Right	18	36	
	Left	20	40	
	Bilateral	12	24	
Total		50	100	
Type of lesion	Cavitary	Single	20	40
		Multiple	3	6
	Non-Cavitary	Diffuse infiltration	14	28
		Localized infiltration	13	26
Total		50	100	
Extent of lesion	Minimal lesion	29	58	
	Moderately advanced	16	32	
	FAR advanced	5	10	
Total		50	100	

The most common bronchoscopic finding was congestion with mild to moderate hyperemia with whitish plaques of variable size in between, observed

in 20 (58.82%) patients. In 9 patients (26.47%) ulceration, erosion or granulation was seen. In many patients with cavitary lesion the mucosa was

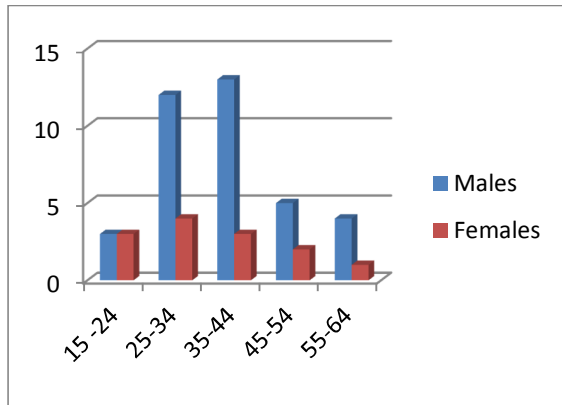


Fig 1: Age wise and gender distribution of patients.

ulcerated & swollen. In 5 patients ulcerative lesions were observed with extensive areas of pulmonary involvement radio graphically. In 3 patients (8.82%) the segmental openings were narrowed and slightly deformed. Intra bronchial growth was seen in 2 patients (5.88%) [Figure 5].

16 out of the total 50 cases were positive by induced sputum (32%). Of the remaining 34 cases which were subjected to bronchoscopy, 26 cases were smear positive for AFB. Thus, active tuberculosis was diagnosed in 42 patients out of the total 50 smear negative cases (84%).

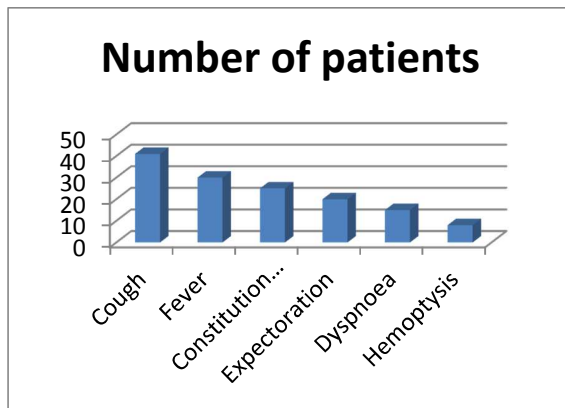


Fig 2: Common symptoms in patients

Bronchoscopy has helped to establish the diagnosis in 2 more patients (Bronchogenic carcinoma). In the remaining 6 patients no diagnosis could be

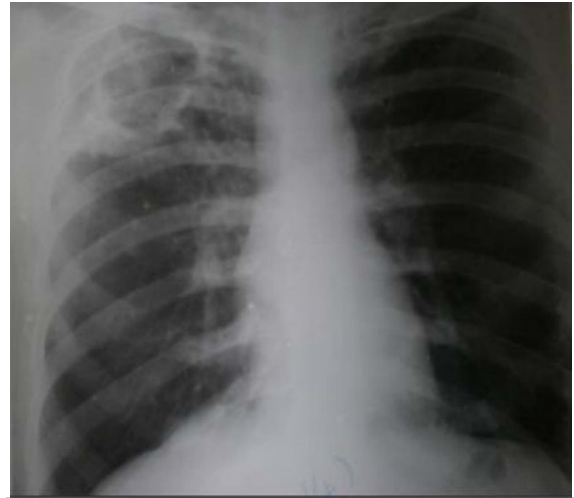

Fig 3: Unilateral lesions

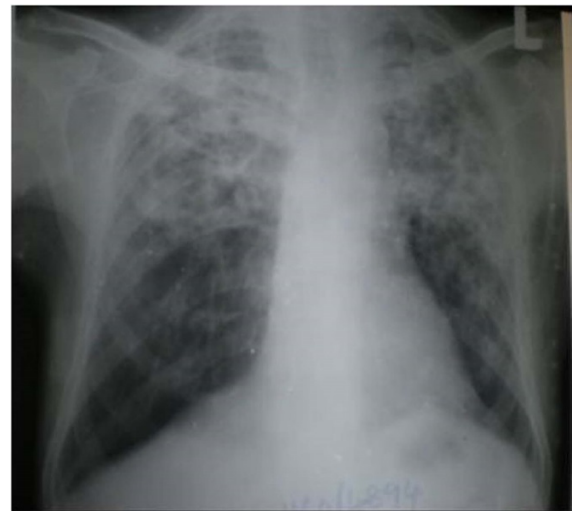

Fig 4: Bilateral lesions

established either because investigations were incomplete or non-contributory [Table 2]. Of the Active Tuberculosis cases, 32% were positive through induced sputum, with only BA, 29.4%, b only PBS, 26.47% and by both BA and PBS, 20.58%.

Table 2: Final diagnosis of patients

Diagnosis	Percentage
Active Tuberculosis	42(84%)
Other diagnosis	2(4%)
No specific diagnosis	6 (12%)

Table 3: Results of our study

Procedure		No of pts	Percentage
Induced sputum		16	32
Bronchoscopy	Only B.A	10	29.41
	Only PBS	9	26.47
	Both B.A and PBS	7	20.58
Total		42	84

B.A-Bronchial aspirate,PBS-Post bronchoscopic sputum

DISCUSSION

The initial diagnostic approach to suspected cases of pulmonary tuberculosis is to demonstrate mycobacterium tuberculosis in stained smears of expectorated sputum. However, in a large proportion of patients, repeated sputum smear examination for acid fast bacilli may remain negative in spite of clinical profile and radiological lesions being consistent with the diagnosis of pulmonary tuberculosis. Even the cultures of sputum may be non contributory; the difficulty is further compounded by the fact that culture of mycobacterium requires 6-8 weeks for final report.

In the earlier days of rigid bronchoscopy; patients with tuberculosis were seldom subjected to bronchoscopy for diagnostic purpose. With the advent of fiber-optic bronchoscopy, smear and culture for mycobacteria from the bronchial aspirate, bronchial brushing, bronchial washing, broncho-

alveolar lavage fluid, post-bronchoscopy sputum and biopsy material have all been used in various studies for diagnosing pulmonary tuberculosis.

In present study 72% of patients had duration of illness less than 3 months. Mean duration of illness was 2.78 months .In a similar study by Purohit et al^[11] nearly half of the patients had illness for less than three months duration and only 15 (30%) had illness of six month duration .In another study by Mohan et al^[12] mean duration of illness was 10.3 weeks, ranging from 3 to 24 months.

In present study 82% patients had cough, 60% had fever, 40% had expectoration varying from 25ml per day to 100ml per day, 30% had dyspnea varying from grade I to grade III, 16%of patients had hemoptysis which was mild and 50%of patients had constitutional symptoms like loss of appetite, loss of weight and easy fatigability. Results from similar studies in shown in Table 3.

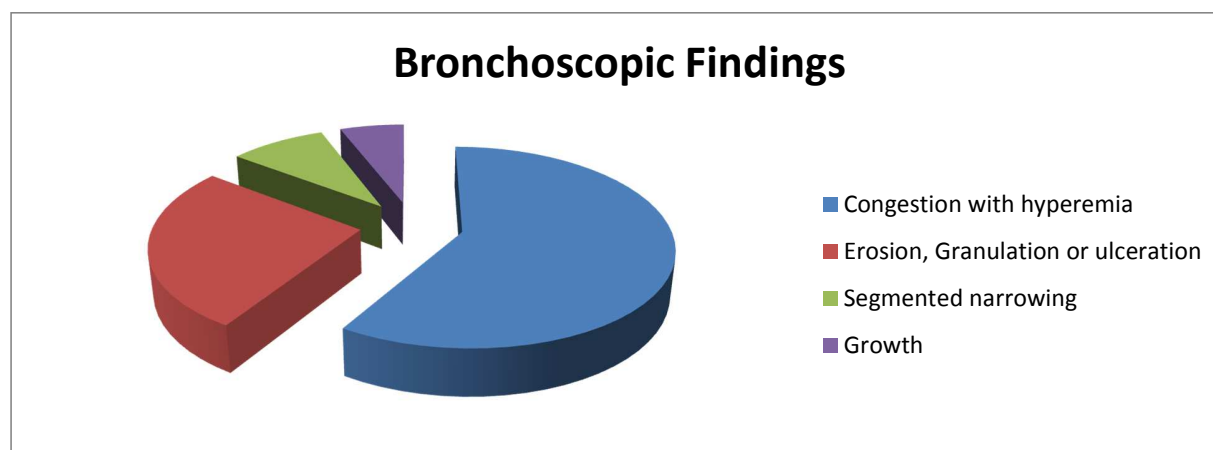


Fig 5: Bronchoscopic findings

Table: 3: Comparison of symptoms in similar studies.

Symptoms	Present study	Kulpati et al ⁷	Mohan et al ¹²	Purohit et al ¹¹
Cough	82%	55%	68%	100%
Expectoration	40%	50%	54%	66%
Fever	60%	50%	70%	64%
Haemoptysis	16%	20%	28%	36%
Constitutional symptom	50%	40%	30%	38%

In our study, yield of induced sputum was 32%. It is comparable to a study in Department of Internal Medicine, Eul-Ji Medical College, Taejon, Korea^[13] where Sensitivity of AFB smear were 36% (17/47) in induced sputum and 53%(25/47) in bronchoscopy, and to a study in Department of Tuberculosis & Chest Diseases, Pt. B.D. Sharma Post Graduate Institute of Medical Sciences, Rohtak^[14] where 38 out of 97 successfully induced sputum samples were found positive for AFB on direct smear examination (Z-N stain). 29/76 (38.15%) patients, who were previously smear negative with spontaneous sputum, were found positive with induced sputum. Yet in other study at Military Hospital, Rawalpindi, from January to December 2006¹⁵, smear positivity with induced sputum samples was 21.21%.

In present study 58.82% of cases showed congestion with hyperemia of bronchial mucosa on bronchoscopy, 26.47% of patients had erosion, ulceration and granulation on bronchoscopy, all these were diagnosed as active pulmonary tuberculosis by demonstration of acid fast bacilli in bronchial aspirate smear or post-bronchoscopy sputum. While segmental narrowing was observed in 8.82% patients. 5.88% of patients presented as intraluminal growth. Some cases had multiple findings on bronchoscopy. Kulpati et al^[7] observed coating of mucosa of involved segments with yellowish white secretions in almost all patients and also revealed mild to moderate hyperemia after bronchial wash. Segmental bronchus was narrowed in 20% patients, and ulceration was seen in 20% patients.

Purohit et al^[11] reported ulceration in 64% of patients, 60% had frothy secretion for the bronchus. A moderate hyperemia of bronchial mucosa was observed in all the patients.

Similar observation were made by Panda et al^[16], who reported that 44% had normal bronchial mucosa, 21% had unhealthy mucosa with granulations, 35% had discharge of muco-pus from bronchus, 5% had growth, 3% had external compression and 3% had bleeding from bronchus and some cases had multiple findings.

Flexible fiberoptic bronchoscopy provided material for early diagnosis e.g. bronchial washing for smear preparation. Danek and Bower^[17] and Purohit et al^[11] demonstrated acid fast bacilli in 34% and 42% respectively where as in study by Kulpati et al^[7] 40% were positive. In our study 29.41% were positive by bronchial wash, 26.47 were positive for post bronchoscopic sputum smear for AFB and total yield of bronchoscopy was 76.47 which is comparable to other studies.

CONCLUSION

In fresh sputum smear negative for pulmonary tuberculosis, immediate diagnosis is very difficult as the sputum culture takes long time and a definite serological test is not available. It appears therefore that any procedure that will aid in establishing early diagnosis, would be of great value in reducing the progression of disease, spread to others, morbidity etc. Our study suggests that induced sputum and fiberoptic bronchoscopy with bronchial aspirate and post bronchoscopic sputum can provide excellent material for diagnosis of suspected cases of Pulmonary Tuberculosis in whom smears of expectorated sputum do not reveal mycobacteria. The minimum patient discomfort, reduced complications and relatively good yield makes these procedures justifiable in the diagnosis of fresh smear negative pulmonary tuberculosis.

Another major advantage is that an alternative diagnosis like Bronchogenic Carcinoma can be made, where early diagnosis is of even greater importance. This makes fiberoptic bronchoscopy an essential requisite for respiratory work up not only in confirming tuberculosis but also in establishing diagnosis of non tuberculous pathology.

REFERENCES

1. Smith I. Mycobacterium tuberculosis Pathogenesis and Molecular Determinants of Virulence. *Clinical Microbiology Reviews* 2003;16(3):463-496.
2. Lawn SD, Zumla AI. "Tuberculosis". *Lancet* 2011;9:57-72.
3. Kumar AB, Kumar B, Ramesh D, Gobinath M. *IJPRBS* 2014;3(5):406-436.
4. Onyango RO. State of the Globe: Tracking Tuberculosis is the Test of Time. *Journal of Global Infectious Diseases*. 2011;3(1):1-3.
5. Sharada MP, Nelliyanil M. Profile of paediatric tuberculosis patients in Bangalore Mahanagar Palike area. *NTI Bulletin* 2009;45:1-4.
6. Therese KL. A Pilot Study on the Detection of Multidrug Resistant Tuberculosis in Hospital Based Population of Chennai, India. *J Med Microb Diagn* 2014;3:153.
7. Kulpati DDS, Heera HS. Diagnosis of smear negative pulmonary tuberculosis by flexible fibreoptic bronchoscopy. *Indian J. Tuberc.* 1986;33:179-82.
8. Francis J. Curry National Tuberculosis Center: Tuberculosis Infection Control. A Practical Manual for Preventing TB 2007;6:74-86.
9. Zainudin BM, Wahab SA, Rassip CN, Ruzana MA, Tay AM. The role of diagnostic fiberoptic bronchoscopy for rapid diagnosis of pulmonary tuberculosis. *Med J Malaysia*. 1991;46:309-313.
10. Palenque E, Amor E, Bernaldo de Quiros JC. Comparison of bronchial washing, brushing and biopsy for diagnosis of pulmonary tuberculosis. *Eur J Clin Microbiol* 1987;6:191-2.
11. Purohit SD, Sisodia RS, Gupta PR, Sarkar SK, Sharma TN. Fiberoptic bronchoscopy in the diagnosis of smear negative pulmonary tuberculosis. *Lung India* 1983;1:143-6.

12. Mohan A, Pande JN, Sharma SK, Rattan A, Guleria R. Bronchoalveolar lavage in pulmonary tuberculosis, a decision analysis approach. *QJ Med* 1995;88:269-276.
13. Na MJ. Comparison of Induced Sputum and Bronchoscopy in Diagnosis of Active Pulmonary Tuberculosis; *Korean J Med*. 1998;55(1):75-82.
14. Gupta KB, Garg S. Sputum induction a useful tool in diagnostic respiratory diseases. *Lung India* 2006;(23):82-6.
15. Atiq-ur-Rehman M, Naseem A, Hussain T. Comparison of Diagnostic Yield of AFB with Sputum Induction to Spontaneous Sputum Examination in Suspected Pulmonary Tuberculosis. *Journal of the College of Physicians and Surgeons Pakistan* 2009 19(8):506-50.
16. Panda BN, Rajan KE, Jena J, Nema SK, Patil AP. Diagnostic yield from flexible fibreoptic bronchoscopy in sputum smear negative pulmonary tuberculosis cases. *Ind J Tub* 1995;42:207-209.
17. Danek SJ, Bower JS. Diagnosis of pulmonary tuberculosis by flexible fiberoptic bronchoscopy. *Am Rev Respir Dis* 1979;119:677-679.

How to cite this article: Madas S, Reddy MC, Bindu HM, Koutam K. Role of Induced Sputum, Bronchial Aspirate and Post Bronchoscopic Sputum in the Diagnosis of Sputum Smear Negative Pulmonary Tuberculosis. *Ann. Int. Med. Den. Res.* 2015;1(3):185-90.

Source of Support: Nil, **Conflict of Interest:** None declared