

# Effects of Methotrexate on Testis: An Experimental Study on Albino Rats

Gulshan Battan<sup>1</sup>, Rati Tandon<sup>1</sup>, Shaista M Vasenwala<sup>2</sup>, Nafis Ahmad Faruqi<sup>3</sup>

<sup>1</sup>Resident, Department of Anatomy, JNMC, AMU, Aligarh, UP

<sup>2</sup>Professor, Department of Pathology, JNMC, AMU, Aligarh, UP

<sup>3</sup>Professor, Department of Anatomy, JNMC, AMU, Aligarh, UP

## ABSTRACT

**Background:** Methotrexate was often used for prolonged period for satisfactory therapeutic results enhancing the chance of toxicity. Methotrexate was known for its toxic effects involving most of the organs of body including testis. Attempts were made earlier to find out changes in testicular structure of methotrexate toxicity, but details of histopathological reports were not available in literature. The aim of the present study was to see the histopathological changes on testis after giving methotrexate. **Materials and methods:** Twelve male albino rats were divided into experimental and control groups of equal animals. Former received methotrexate, 1mg per Kg, intraperitoneally, weekly for 6 weeks. Testicular tissue after perfusion fixation, were processed for wax embedding technique and the sections thus obtained were stained with H/E stains. **Result:** Marked histopathological alterations in seminiferous tubules, cells in its wall undergoing spermatogenesis and Leydig cells were observed. **Conclusion:** In younger patients the risk of infertility should be kept in mind while using it for prolonged period.

**Keywords:** Methotrexate, Testis, Infertility, Histopathology

## INTRODUCTION

Methotrexate is folate antagonist.<sup>[1]</sup> It is apparently curative in choriocarcinoma and is highly effective in maintaining remission in children with acute leukemia.<sup>[2]</sup> Recently methotrexate is drug of choice for most patients of rheumatoid arthritis including cases of juvenile rheumatoid arthritis. This has made methotrexate as DMARD (Disease Modifying Anti Rheumatic Drug) for said cases. Unfortunately the drug is used for prolonged period for satisfactory therapeutic results<sup>[3]</sup> enhancing the chance of toxicity in patients. Methotrexate is known for its toxic effects involving most of the organs of the body which include bone marrow, liver, lung, kidney, gut<sup>[4]</sup>, central nervous system<sup>[5]</sup> and gonads<sup>[6]</sup>. Gonadal involvement was the most alarming aspect of methotrexate toxicity because of its direct effect on fertility. Several case reports documented sterility in men using methotrexate<sup>[7-11]</sup> due to decrease in sperm count and its altered quality. Reports available on effects of methotrexate on spermatogenesis<sup>[12,13]</sup> and steroidogenesis<sup>[14]</sup> are scanty. Some histomorphometric effects e.g., reduction in diameter of seminiferous tubules, spermatocytes and spermatids were also noted down by some earlier scientists.<sup>[15,16]</sup>

But in all the above studies detailed histopathological changes of testis such as descriptions about changes in seminiferous tubules, Leydig cells, Sertoli cells, germ cells, basement membrane were lacking. The aim of the present study is to find out detailed histopathological changes in testis after exposing the experimental rats to therapeutic dose of methotrexate.

## MATERIALS AND METHODS

Adult albino male rats, weighing 190-200 gms, were used. Animals were divided into equal number of experimental and control groups i.e., 6 each. Diet was standard pellet laboratory diet (Lipton India Limited) and water ad-libitum. Animals of control group received normal saline injection, 1ml intraperitoneally weekly for same duration as animals of experimental group which received methotrexate, 1mg per kg intraperitoneal injection, weekly, for 6 weeks. The animals of both the experimental and control groups were anaesthetized by giving injection Nembutol 30 mg per kg, intraperitoneally. The heart was exposed by thoracotomy. The needle of the blood transfusion set was introduced into the left ventricle (apex) and a nick was made in the right atrium. After saline wash, Karnovsky's fixative was infused till the body showed signs of fixation. First of all, a longitudinal incision was given in ventral wall of scrotum to right side of midline. Right half of scrotal sac was opened and testis dissected out. Similarly a second longitudinal incision was given in ventral wall of scrotum to left of midline and left testis was dissected out in the scrotal sac. Tissue of 2-

### Name & Address of Corresponding Author

Dr. Rati Tandon  
Senior Resident,  
Department of Anatomy,  
JNMC, AMU, Aligarh, UP (India)  
E mail: [rati2011@gmail.com](mailto:rati2011@gmail.com)

3 mm was procured from both control and experimental testes. Sections of 10 µm thickness by wax embedding technique, were obtained and placed on slides. Slide was kept in haematoxylin for 10 min. and then washed with tap water to remove excess haematoxylin. The slide was then dipped in Eosin (1%) for 2 min. and washed with water. Permanent mounting in DPX was done [Figure 1].

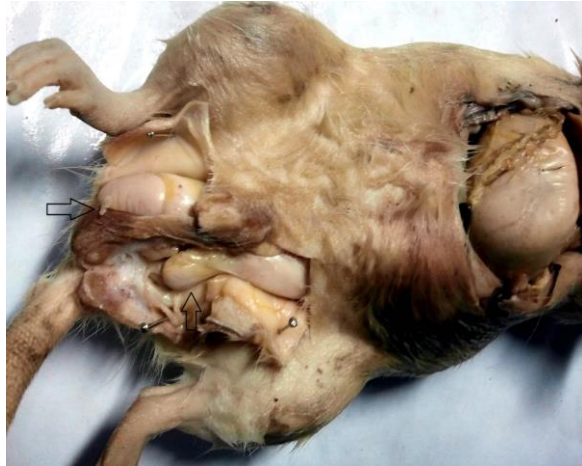

Fig. 1: Bilateral dissection of scrotum showing testis of both sides in male albino rat (testes are shown by arrows).

## RESULTS

In control group the testis showed seminiferous tubules of equal size with active spermatogenesis and spermiogenesis [Figure 2]. Primary spermatocytes in adluminal compartment are observed as larger cells with lighter colour nuclei. Clusters of mature sperms in the centre of tubules show oval blue sperm heads and eosinophilic tails. Triangular pale columnar Sertoli cells are radially arranged in the tubule resting at the basement membrane. The nucleus is round with one nucleolus, chromatin is fine and cytoplasm is pale. Small group of eosinophilic Leydig cells are present in intertubular area. These are polyhedral cells in groups with round nucleus and highly eosinophilic cytoplasm [Figure 3].

In the experimental group seminiferous tubules are irregular in outline and disrupted showing marked degenerative changes [Figure 4]. The seminiferous tubules show severe edema separating the developing germ cells [Figure 5,6]. There is rupture of basement membrane [Figure 4,7]. Spermatogenesis and spermiogenesis is decreased [Figure 5]. Number of mature sperms is also decreased [Figure 8]. The spermatogonia are smaller in size and detached from basement membrane [Figure 9]. Very few sperms are seen in the lumen. No sperm heads are discernible, only eosinophilic tails are seen [Figure 9]. Primary

spermatocyte in adluminal area show lighter colour nuclei and shrinking of cytoplasm as lytic change [Figure 9]. Sertoli cells are of small size with irregular borders and show degenerative changes [Figure 9]. There is presence of both intratubular and intertubular edema [Figure 8]. There is congestion of lymphatics and blood vessels [Figure 6]. Mild focal lymphocytic infiltration of tunica albuginea is present [Figure 4]. In some cases, there is extrusion of tubular contents in intertubular area due to rupture of basement membrane [Figure 7].

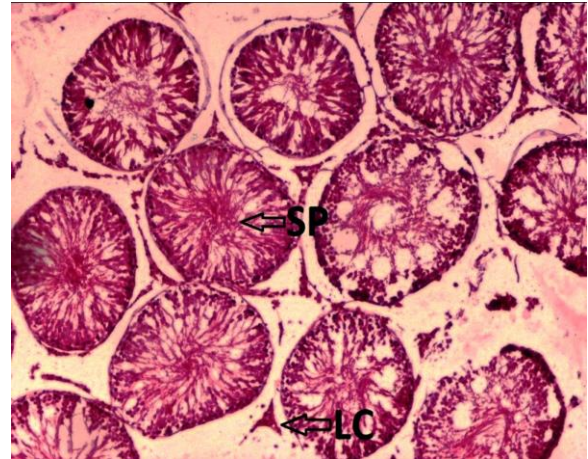


Fig. 2: Testis, Control rat, H&E×10

Seminiferous tubules of equal size with active spermatogenesis are observed. Spermatogonia at the basement membrane, spermatocyte and spermatozoa (SP) in lumen is seen. Groups of eosinophilic Leydig cell (LC) in intertubular space are present [Figure 2].

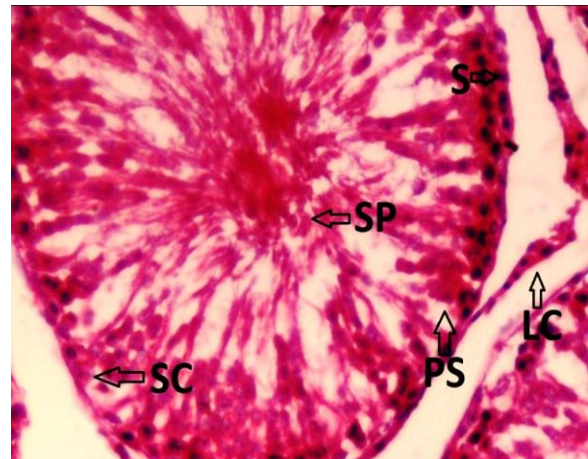


Fig. 3: Testis, Control case 1, H&E×40

Tubules show spermatogonia (S) at the basement membrane with round dark nucleus and eosinophilic cytoplasm. Primary spermatocyte (PS); larger cells, lighter colour nuclei are present. Cluster of mature

sperms (SP) in centre of tubules; blue sperm head & eosinophilic tail are present. Triangular Sertoli cell (SC) at basement membrane; nucleus round, one nucleolus, fine chromatin, pale cytoplasm are present. Leydig cells (LC) in group; in intertubular space, polyhedral, eosinophilic cytoplasm are seen [Figure 3].

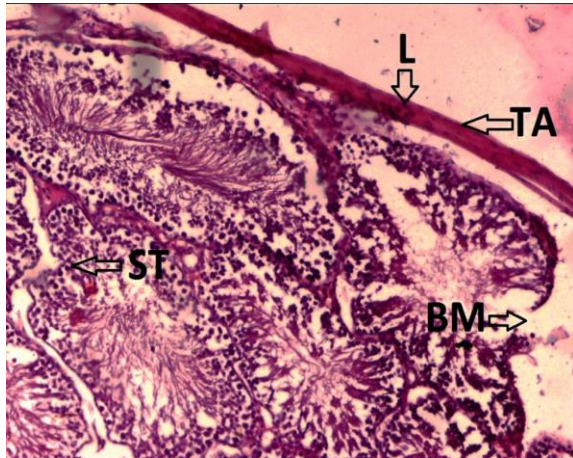


Fig. 4: Testis Experimental rat, H&E× 10

Seminiferous tubules (ST); edematous, irregular, show degenerating cells detaching from BM are seen. Rupture of BM, few mature sperms, lymphocytic infiltration (L) in tunica albuginea (TA) are observed [Figure 4].

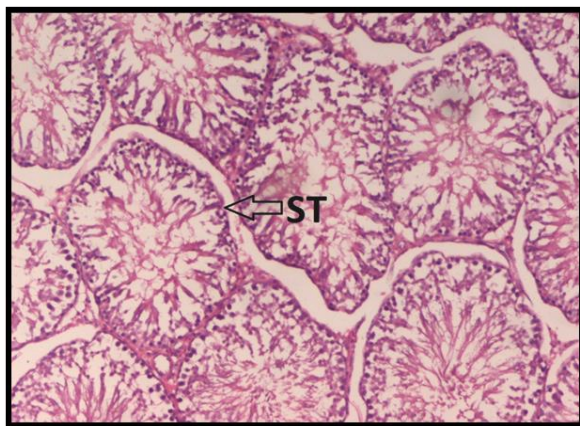


Fig. 5: Testis Experimental rat, H&E× 10

Seminiferous tubule (ST) are disrupted, intra- & inter-tubular edema, separation of germ cells are seen. Spermatogenesis, spermiogenesis are decreased [Figure 5].

Seminiferous tubules (ST) are irregular, edematous. Detached spermatogonia(S) from basement membrane are present. Decreased number & degeneration of germ cells is observed. Degeneration of Sertoli cells (SC) & Leydig cells (LC) occurs.

Congestion of blood vessels (BV) & lymphatics is seen [Figure 6].

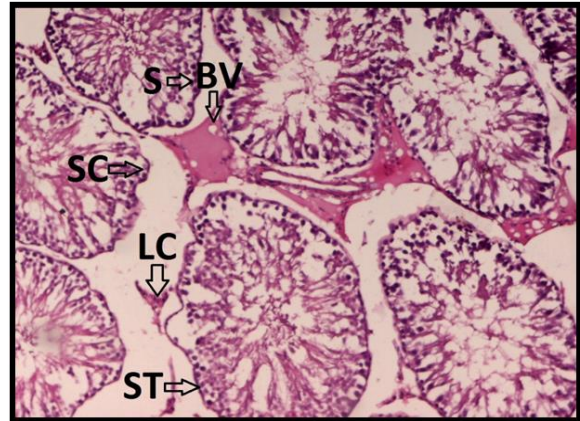


Fig. 6: Testis, Experimental rat, H&E× 10

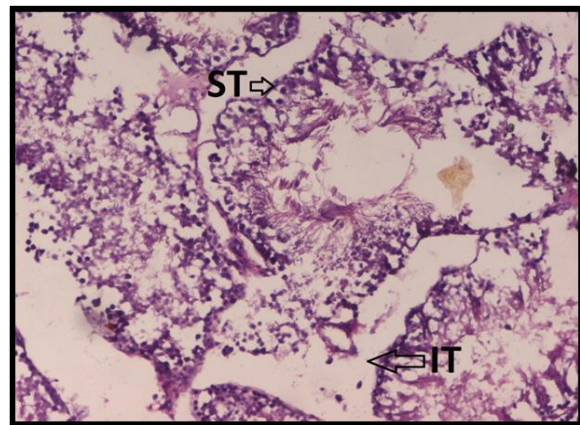


Fig. 7: Testis, Experimental rat, H&E× 10

Irregular edematous distorted ruptured seminiferous tubules (ST), ruptured basement membrane, extrusion of tubular contents into intertubular (IT) space are observed. Lysis, degeneration of germ cells, small dark nuclei, loss of cytoplasm are seen in experimental rats [Figure 7].

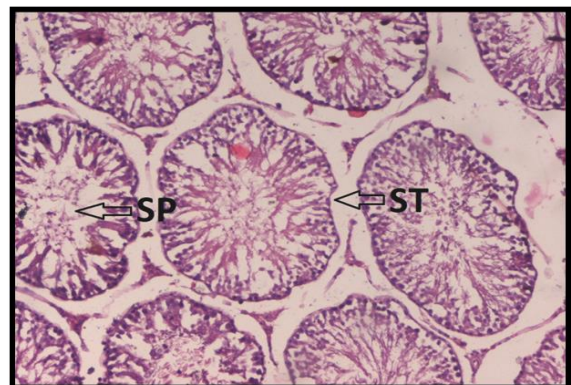


Fig. 8: Testis Experimental case 2, H&E× 10

Seminiferous tubules shows irregular, intra & intertubular edema. Decreased number of mature sperms (SP) in tubules are found [Figure 8].

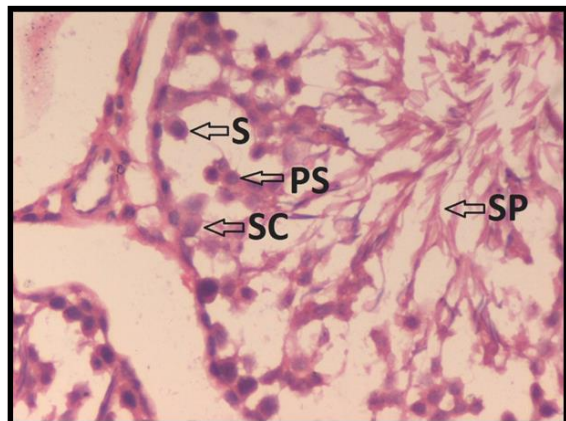


Fig. 9: Testis ,Experimental case 1 , H&E× 40

Tubules with severe edema and separated germ cells are found in experimental group. Spermatogonia (S); detach from basement membrane, large nucleus, condensed chromatin, eosinophilic cytoplasm are observed. Primary spermatocyte (PS) in adluminal area, lighter colour nuclei, scanty cytoplasm as lytic change are seen. Very few sperm's (SP) heads and eosinophilic tail are found. Sertoli cells (SC) are found to be degenerated.

## DISCUSSION

Chemotherapeutic agents are extensively used for the treatment of various types of cancers. These drugs bring drastic improvement in the illness of patient as well as increase the life expectancy of cancer patients. But most of chemotherapeutic agents are mutagenic and carcinogenic.<sup>[10]</sup> Koehler et al. were the first to find out effects of methotrexate on rabbit testis. They evaluated fertility rate and spermatogenetic activity using tubular fertility index.<sup>[17]</sup> Badri et al. reported decrease in steroidogenesis due to decrease in testosterone level by effect of methotrexate after intramuscular injection.<sup>[14]</sup> Shreshta et al. studied effect of intraperitoneal injection of methotrexate on rat testis. They revealed decreased diameter of seminiferous tubules, increased interstitial space as well as distortion of morphology of Leydig cells.<sup>[12]</sup> Padmanabhan et al. exposed mice with intraperitoneal injection of methotrexate weekly. They reported reduced sperm count and increased occurrence of sperm head abnormalities. Sperm count is an important measure of fertility. In this study, they institute that decline in sperm count resulted due to the interference in the spermatogenesis process and

the abolition of sperm cells at different stages of development.<sup>[13]</sup>

Another important factor determining the fertility of males is sperm motility. Studies establish that MTX - treated mice demonstrates fall in sperm motility. The status of oxidative stress during MTX administration accompanied by increased lipid peroxidation in various tissues is responsible for diminished sperm motility <sup>[13,14]</sup> Sukhotnik et al. reported effects of intra-peritoneal injection of methotrexate on testis of rats. They found impaired spermatogenesis and increase in germ cell apoptosis.<sup>[18]</sup> Pectasides et al. observed testicular function in poor risk non-seminomatous germ cell tumours in patients treated with methotrexate. They demonstrated recovery of spermatogenesis after treatment and found the Leydig cell function unaffected. Alteration in hormonal level (FSH) was detected after the accomplishment of chemotherapy whereas serum LH level was unaffected by chemotherapy. <sup>[19]</sup> These results indicate that the malfunction of male reproductive organs by MTX treatment in young men is not only related with disrupted circulating levels of hormones and histo-architecture of tissues but also incongruities in steroidogenic genes and hormone regulated enzyme activities in testes.

## CONCLUSION

The findings of the present study show that therapeutic dose of methotrexate is capable of producing histopathological changes in testis. Thus use of methotrexate should be judicious as it affects the testis causing inflammatory changes resulting in possibly lowering of fertility rate. It is safer to use this drug in patients who have completed their family.

## REFERENCES

- 1.Saxena AK, Singh D, Singh G. Structural interaction between drug - DNA and protein- A novel approach for bioinformatics in medicine. *Biomedical Research*. 2009;20(1):28-34.
- 2.DeVita VT, Chu E. A History of Cancer Chemotherapy. *Cancer Res* 2008;68;8643-53.
- 3.Lennard L. Therapeutic drug monitoring of antimetabolic cytotoxic drugs. *Br J Clin Pharmacol*. 1999;47(2):131-143.
- 4.Gibson RJ, Bowen JM. Biomarkers of regimen-related mucosal injury. *Cancer Treat Rev*. 2011;37(6):487-93.
- 5.Argyriou AA, et al. Chemotherapy-induced peripheral neurotoxicity (CIPN): an update. *Crit Rev Oncol Hematol*. 2012;82(1):51-77.
- 6.Blumenfeld Z. Chemotherapy and fertility. *Best Pract Res Clin Obstet Gynaecol*. 2012;26(3):379-90..
- 7.Ragheb AM, Sabanegh ES Jr. Male fertility-implications of anticancer treatment and strategies to mitigate gonadotoxicity. *Anticancer Agents Med Chem*. 2010;10(1):92-102.

8. Weissbach L, Lange CE, Rodermund OE, Zwicker H, Gropp A, Pothmann W. Fertility disturbances following treatment of patients with testicular tumours. *Urologe A*. 1974;13:80-5.
9. Hinkes E and Plotkin D. Reversible drug-induced sterility in a patient with acute leukemia. *JAMA*. 1973; 223:1490-1.
10. Sussman A and Leonard JM. Psoriasis, methotrexate, and oligospermia. *Arch Dermatol*. 1980;116:215-7.
11. Shamberger RC, Sherins RJ, Rosenberg SA. The effects of postoperative adjuvant chemotherapy and radiotherapy on testicular function in men undergoing treatment for soft tissue sarcoma. *Cancer*. 1981;47:2368-74.
12. Shrestha S, Dhungel S, Saxena AK, Bhattacharya S, Maskey D. Effect of methotrexate (mtx) administration on spermatogenesis: an experiment on animal model. *Nepal Med Coll J*. 2007;9(4):230-3.
13. Padmanabhan S, Tripathi DN, Vikram A, Ramarao P, Jena GB. Cytotoxic and genotoxic effects of methotrexate in germ cells of male Swiss mice. *Mutat Res*. 2008;655(1-2):59-67.
14. Badri SN, Vanithakumari G, Malini T. Studies on methotrexate effects on testicular steroidogenesis in rats. *Endocr Res*. 2000;26(2):247-62.
15. Johnson FE, Farr SA, Mawad M, Woo YC. Testicular cytotoxicity of intravenous methotrexate in rats. *J Surg Oncol*. 1994;55(3):175-8
16. Chelab KG, Majeed SK. Histopathological effects of methotrexate on male and female reproductive organs in white mice. *Bas J Vet Res*. 2009;8(2):120-4.
17. Koehler M, Waldherr R, Ludwig R, Heinrich U, Brandeis WE. Effect of methotrexate on rabbit testes. Part 1: Morphological changes. *Pediatr Hematol Oncol*. 1986;3(4):325-34.
18. Sukhotnik I, Nativ O, Roitburt A, Bejar D, Coran AG, Mogilner JG, Nativ O. Methotrexate induces germ cell apoptosis and impair spermatogenesis in a rat. *Pediatr Surg Int*. 2013;29(2):179-84.
19. Pectasides D, Pectasides E, Papaxoinis G, Skondra M, Gerostathou M, Karageorgopoulou S, Kamposioras C, Tountas N, Koumariou A, Psyri A, Macheras A, Economopoulos T. Testicular Function in Poor-Risk Nonseminomatous Germ Cell Tumors Treated with Methotrexate, Paclitaxel, Ifosfamide, and Cisplatin Combination Chemotherapy. *J Androl*. 2009; 30(3):280-6.

**How to cite this article:** Battan G, Tandon R, Vasenwala SM, Faruqi NA. Effects of Methotrexate on Testis: An Experimental Study on Albino Rats. *Ann. Int. Med. Den. Res*. 2015;1(3):170-74.

**Source of Support:** Nil, **Conflict of Interest:** None declared