

Surgical Management of Posterior Malleolus Fracture

V Venu Gopal¹

¹Associate Professor, Department of Orthopedics, Fathima Institute of Medical Sciences, Kadapa.

Received: June 2015

Accepted: August 2015

ABSTRACT

Background: Posterior malleolus fractures mostly occur in association with fractures of other malleoli. The current recommendation is fixation based on the size of the fragment. **Methods:** A retrospective study of 30 cases of posterior malleolus was conducted. There were 4 cases in type 1, 8 cases in type 2, 7 cases in type 3, 10 cases in type 4 and type 5 there was 1 case. Type 1 were not operated and type 5 were left alone in POP cast for 6 weeks. Type 2, 3 and 4 were operated either by cannulated cancellous screw by trans Achilles approach, when the fragment was less than 20% of the surface area in 6 cases. When the surface exceeded 15%, those cases were treated with osteosynthesis by posterolateral approach using a buttress plate principle. **Results:** Good results were seen in all cases except one which developed post operative infection and had early arthritis. **Conclusion:** Radiological studies are essential to plan and posterolateral approach provides a good exposure for management of posterior malleolar fractures.

Keywords: Posterior malleolar fracture, fixation, 3D CT scan.

INTRODUCTION

Posterior malleolus fractures are common in ankle fractures. They usually occur in association with fractures of the other malleoli, hence resulting in an unstable trimalleolar configuration. The posterior malleolus fracture most commonly occurs with the supination- external rotation and pronation- external rotation fracture patterns. Though various attempts at classification and guidelines of treatment were made, there is no clear consensus regarding the minimum size of the fracture that requires fixation. Current trend is directed towards an anatomic reduction and fracture fixation of posterior malleolar fragments. Fixation methods vary based on the size of the fragment.

Name & Address of Corresponding Author

Dr. V Venu Gopal,
Associate Professor,
Department of Orthopedics,
Fathima Institute of Medical Sciences,
Kadapa.

MATERIALS AND METHODS

Our study consisted of 30 patients who had posterior malleolus fractures. All patients were subjected to plane radiographs of ankle AP and lateral views. CT scans were taken to delineate the morphology of the fracture fragment and estimate the size of the fragment. Fractures were classified using Bartonicek et al created classification which addresses the morphology of the fracture types and use this as a

guide towards management [Figure 1]. There were four cases in type 1, 8 cases in type 2, 7 cases in type 3, 10 cases in type 4 and type 5 there was 1 case. Type 1 was not operated and type 5 were left alone in POP cast for 6 weeks. Type 2, 3 and 4 were operated either by cannulated cancellous screw by trans Achilles approach, when the fragment was less than 20% of the surface area in 6 cases. When the surface exceeded 15%, those cases were treated with osteosynthesis by posterolateral approach using a buttress plate principle.

Classification

1. Type 1 includes an extra- incisural fragment with an intact fibular notch (managed non operatively).
2. Type 2 involves a posterolateral fragment extending into the fibular notch [Figure 2,3].
3. Type 3 is a posteromedial 2-part fragment involving the medial malleolus.
4. Type 4 is a large posterolateral triangular fragment [Figure 4].
5. Type 5 includes the remaining fractures that cannot be classified and include irregular fragments.

Indications of surgery

Though there are no clear cut guidelines for conservative and operative treatment, we operated if one of the following criteria were met.

1. Bartonicek at al morphological classification type 2-5
2. Fragment size > 25 - 33%
3. Displacement > 2 mm
4. Ankle instability with concomitted syndesmotomic injury.

Timing of surgery

Surgery is usually conducted within first 72 hours. If there is excessive swelling in ankle or blisters, surgery is performed after wrinkling occurs.

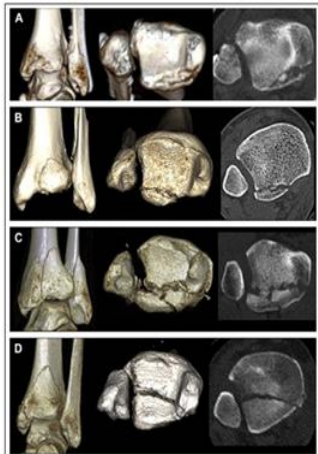


Fig.1. Posterior Malleolus Fracture classification by Bartonicek et al

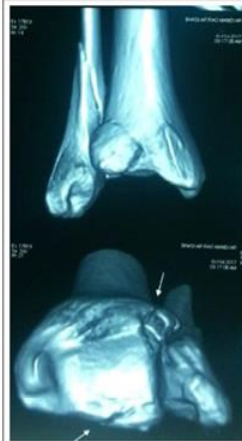

Fig.2: Posterior Malleolus Fracture Type 2 - Extending into Fibular notch

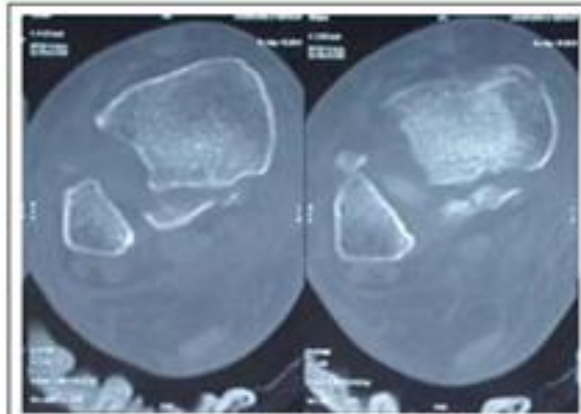


Fig.3: Posterior Malleolus Fracture Type 2

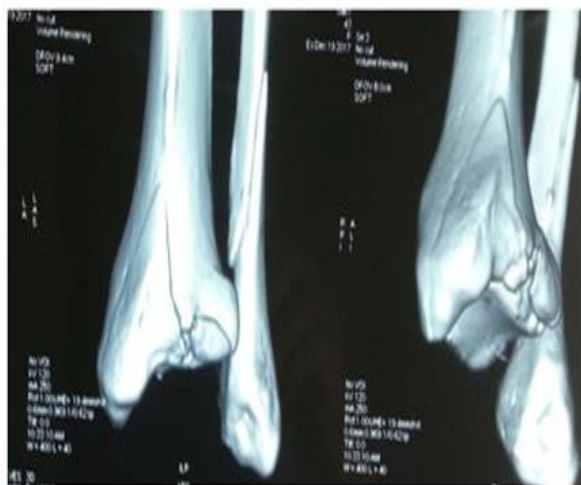

Fig.4: Posterior Malleolus Fracture Type 4 - Large Posterior-Lateral Fragment

Surgical technique

Surgery can be performed in prone position or the patient may be placed in the lateral decubitus position [Figure 5]. A posterolateral approach is performed with the patient in the lateral position. The longitudinal incision is placed just medial to the posterior border of the fibula. This gives good access to the posterior malleolus and optimal access to the lateral malleolus through mobilisation of peroneal musculature. The lesser saphenous vein and sural nerve are identified and protected. The sural nerve courses from medial to lateral and crosses the lateral border of the Achilles tendon on average 9.8 cm proximal to its insertion in the calcaneus. At a point 7 cm proximal to the tip of the lateral malleolus, the nerve is on average 26 mm posterior to the edge of the fibula. Interval between the peroneal tendons and Achilles tendon more medially is exploited. The Flexor hallucis longus is lifted off sharply from the posterior tibia allowing access to the posterior malleolus. Care is taken to preserve the posterior inferior tibiofibular ligament attachment to the fragment and the joint capsule, which means the fragment should be hooked open from medial to lateral for joint inspection. Care should be taken to merely to clean and define the fracture edge and not to be vascularise the fragment. The posterior malleolus fragment is reduced directly and fixed temporary with k wires. Depending on its size and morphology, fragment is fixed with cannulated screws for small fragment T plate as a buttress [Figure 6,7]. Image intensifier can be used to confirm the accuracy of reduction, fixation and ensure extra articular screw placement.

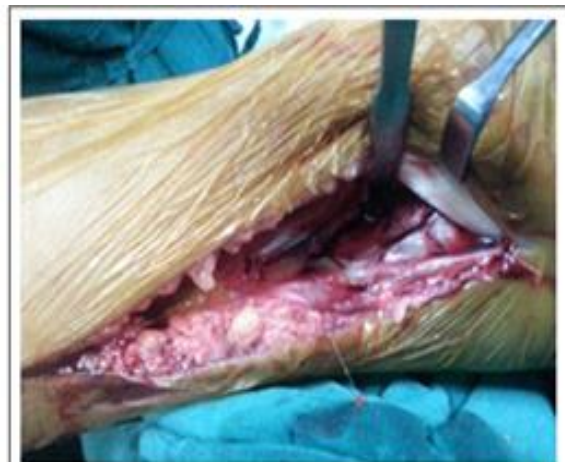

Fig.5: Patient in Floppy Lateral Position with Posterior-lateral approach and mobilisation of Peroneal Musculature

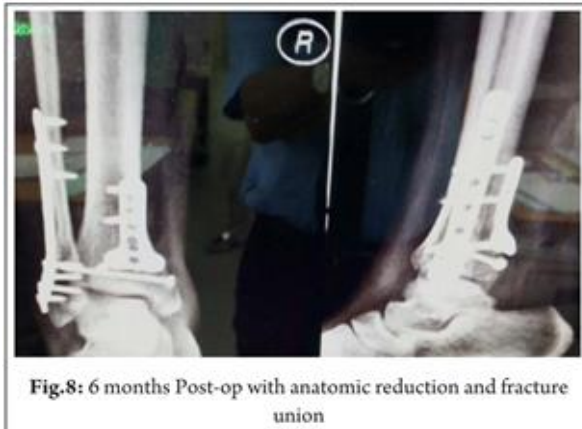
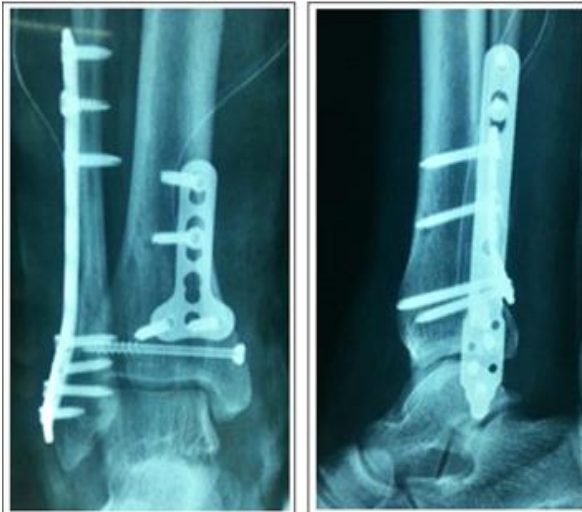

Fig.8: 6 months Post-op with anatomic reduction and fracture union

Rehabilitation

Patient is given limb elevation, active toe movements is started immediately post-surgery. Rehabilitation is as per standard protocol. Plaster slab is removed at 3 weeks and range of movement exercises for ankle are begun. Patient is allowed to partial weight bearing after 6-8 weeks depending on signs of fracture healing clinically and on radiographs. Full weight bearing is allowed only after 3 months



Fig.9: Restoration of articular surface with early mobilisation leads to full gain of function at 6 months follow up

RESULTS

All the patients were followed up to 3 years and we did not see any post traumatic arthritis or avascular necrosis of the talus, except in one case where there was post traumatic arthritis. This case had compound trimalleolar fracture dislocation and he had developed superficial infection which healed after 6 weeks. The other patients were having good range of ankle motion and were functionally back to per injury activities [Figure 7, 8].

DISCUSSION

Though various studies have been conducted on this topic, posterior malleolus still remains a topic of controversy as far as treatment is concerned. Bartonik at al suggested new classification based on The cole fracture mapping technique suggests a continuous spectrum of increasing articular involvement across all included posterior malleolar fractures using the well-defined 2D transverse plane in which the others recently described a basic Y pattern for fractures of the tibial plafond- the pilon map. The current algorithm when 25% to 33% of the tibial plafond is involved, the fragment requires direct fixation seems rather arbitrary, especially when considering that measurements for made on plain lateral radiographs, which are highly unreliable. The concept of Regan and Morrey for fixation based on size and articular involvement has been used for decades, until O' Driscoll showed us that morphology of a coronoid fracture is more important than coronoid fracture height. Advanced imaging techniques improved our understanding of pathoanatomy of posterior malleolar fractures; however, the clinical relevance of the morphology and correlation to the overall ankle fracture pattern has yet to be established.

Lukas Mangnus at al in 2015 concluded that coronoid fracture morphology and pattern proved more important than classic measures of coronoid height and morphology of the posterior malleolar fragment also might be more important than poster malleolar fracture size and articular involvement alone for clinical decision making.

Saygih et al in 2017 found that there has been no significant functional difference found in trimalleolar fracture when posterior malleolar fracture ratio is smaller than 25% in comparison of posterior malleolus fixation, however, the decreased need of trans-syndesmotomic fixation needs to be taken into consideration.

In our experience posterolateral approach enables direct visualisation and reduction of the posterior malleolar fragment. With this approach anatomic reduction and supplementation of fixation with

buttress plate or cannulated cancellous screw from posterior to anterior trans Achilles can be achieved with ease. Fixation of even small fragment leads to anatomic reduction of the tibial plafond, hence improving stability of the ankle and thus helping in early mobilisation. In regards to this, a more aggressive rehabilitation regimen might be warranted which would improve postoperative results.

CONCLUSION

Posterior malleolus fracture is a complex fracture to treat. The key to management is accurate diagnosis based on good radiographs, CT scan preferably with 3D reconstruction to know exact morphology of the fracture and decide plan for management. Fixation restores articular congruity and ankle stability. Fixation of posterior malleolar fracture restores competence of posterior inferior tibiofibular ligament. Surgical management should not be based only upon fragment size but also fracture dislocation, displacement, articular surface congruity, residual tibiotalar subluxation, fragmentation and comminution, and syndesmotic stability. Posterolateral approach to the ankle provides the optimal exposure for direct reduction and adequate fixation of posterior malleolar fractures.

REFERENCES

1. Lauge-Hansen N, Fractures of the ankle: analytic, historical survey as the basis of new experimental, roentgenologic and clinical investigations. Arch surg 1948;56:259-317.
2. Haraguchi N, haruyama H, Toga H, Kato F, Pathoanatomy of posterior malleolar fractures of the ankle. J Bone Joint surg Am 2006; 88: 1085-92.
3. Hoppenfield S, deBoer P. Surgical exposures in orthopaedics: The anatomic approach. 2nd edition Philadelphia: Lippincott, Williams and Wilkins; 1994.
4. Hong CC, Nashi N, Prasad Roy S, Tan KJ. Impact of trimalleolar ankle fractures: How do patients fare postoperatively, Foot Ankle Surg 2014; 20(1): 48-51.
5. Drijfhout van Hoof CC, Verhage SM, Hoogendoorn JM. Influence of fragment size and postoperative joint congruency on long-term outcome of posterior malleolar fractures. Foot Ankle Int 2015; 36(6) 673-6.
6. Mast JW, Teipner WA. A reproducible approach to the internal fixation of adult ankle fractures; Rationale, technique, and early results. Orthop Clin North Am 1980; 11(3): 661-79.
7. Gardner MJ, streubel PN, McCormick JJ, Klein SE, Johnson JE, Ricci WM. Surgeon practices regarding operative treatment of posterior malleolus fracture. Foot Ankle Int 2011; 32(4):385-93
8. Noh KC, Hong DY, Kim YT, Kadakia AR, Park YW, Kim HN. Arthroscopic transfibular approach for removal of bone fragments in posterior malleolar fracture: technical tip. Foot Ankle Int 2015; 36(1): 108-12
9. Webb J, Moorjani N, Radford M Anatomy of the sural nerve and its relation to the Achilles tendon. Foot Ankle Int 2000;21: 475-7.
10. Lawrence SJ Botte MJ. The sural nerve in the foot and ankle: an anatomic study with clinical and surgical implications. Foot Ankle Int 1994; 15(9): 490-4.

11. Franzone JM, Vosseller JT. Posterolateral approach for open reduction and internal fixation of a posterior malleolus fracture-hinging on and intact PITFL to disimpact the tibial plafond: a technical note. Foot Ankle Int 2013; 34(8): 1177-81.
12. Giebel GD, Meyer C, Koebeke J, Giebel G. The arterial supply of the ankle joint and its importance for the operative fracture treatment. Surg Radiol Anat 1997; 19: 231-5.
13. Simanski CJ, Maegele MG, Lefering R et al. Functional treatment and early weight bearing after an ankle fracture: A prospective study. J Orthop Trauma 2006; 20(2):108-14.
14. Carr J. Malleolar fractures and soft tissue injuries of the ankle. In : Browner B, Jupiter J, Levine A, Truitt P, Eds. Skeletal trauma: Basic science, management and reconstruction. 3rd Ed Philadelphia Elsevier science 2003; Vol. 2: pp. 2307-74.
15. Operative versus non operative treatment of posterior malleolus fragment in trimalleolar fracture: A retrospective cohort study. Mehmet Selcuk Saygili, Bans Ozkul, Engin Cetinkaya, Ali Cagri Tekin, Avni Ilhan Bayhan, Ismail Kalkar, Deniz Akbulut, Bilal Demir. Biomedical research 2017;28 914 0: 6498-6503.
16. Posterior malleolar fracture patterns: Lukas Mangnus, MD, Diederik T. Meijer, BSC, Sjoerd A. Stufkens MD, PhD, Jos J. Mellerna, MD, Steller, MD, PhD, Gino M. M. J. Kerkhoffs, MD, PhD and Job N. Doornberg, MD, PhD. J Orthop Trauma volume 29, number 9, September 2015
17. Doornberg JN Ring DC. Fracture of the anteromedial facet of the coronoid process. J bone joint surg Am. 2006; 88:2216-2224
18. Mingo-Robert J, Lopez-Duran L, Galeote JE et al. Ankle fractures with posterior malleolar fragment: management and results. J Foot Ankle Surg. 2011; 50:141-145
19. Bartonick ek J, Rammelt S, Kostilvy K, Vanecek V, Kila D, Tresl I. Anatomy and classification of the posterior tibial fragment in Ankle fractures. Arch Orthop Trauma surg. 2015;135:506-16.

How to cite this article: Gopal VV. Surgical Management of Posterior Malleolus Fracture. Ann. of Int. Med. Den. Res. 2015;1(2):120-23.

Source of Support: Nil, **Conflict of Interest:** None declared