

Wilckodontics- A Magical Wand for Rapid Success-A Review

Nisha. N¹, R Saranyan Ravi², Ann Joseph Anthraper¹, Akhilesh shewale³, Rasila Sainu¹, Surya Rajan Kurian¹

¹Juniour Resident, Department of Periodontia, VMSSDC, Salem, Tamil Nadu, India.

²Professor, Department of Periodontia, VMSSDC, Salem, Tamil Nadu, India.

³Juniour Resident, Department of Periodontia, SDKS dental college and hospital, Nagpur, India.

ABSTRACT

The orthodontic treatment is, perhaps, in terms of duration, the longest-performed dental procedure. In this fast-paced world any treatment that would consume 1 – 2 years is unwelcome. It is universally accepted that if the duration of the orthodontic treatment is reduced, there will be an increased favorable attitude towards the orthodontic therapy. To accelerate the tooth movement the orthodontists and the periodontists together have worked out a success formula which is termed Periodontally Accelerated Osteogenic Orthodontics (PAOO) or wilckodontics. Theoretically this procedure is based on the healing property of bone known as (RAP) regional acceleratory phenomenon. This procedure involves the surgical demineralization of the cortical bone (corticotomy) thereby decreasing the resistance offered by the cortical bone of the teeth to the orthodontic force applied and use of particulate bone grafting. This method not only enhances the width of the alveolar bone but also decreases the duration of the treatment and chances of apical root resorption. It also increases the stability of the treatment by reducing the chances of relapse. A proper case selection, careful surgical procedure and accurate orthodontic movements are important for the success of wilckodontics. This review article includes history, biomechanics, indication, contraindication, case selection, treatment planning, surgical techniques and its modifications.

Keywords: Accelerated orthodontics, Bone activation, Regional acceleratory phenomenon, Wilckodontics

INTRODUCTION

Orthodontic and periodontics specialities have always worked miracles in treating patients together. Periodontal regenerative treatment like tissue engineering, create rapid orthodontic tooth movements.^[1] Synergistic treatment between specialist helps in developing harmony that results in less damage to components of periodontium, the soft tissue around crown and the attachment apparatus that connects the root to bone. So, specialists worked together in a technique called wilckodontics that allows teeth to be moved 2-3 times further in 1/3rd to 1/4th the time required for traditional orthodontic treatment.^[2]

Wilckodontics is periodontally accelerated osteogenic orthodontics (PAOO) otherwise called corticotomy facilitated osteogenic orthodontics. This clinical procedure combines selective alveolar corticotomy, particulate bone grafting and the application of orthodontic forces.^[3] This is based theoretically on the healing pattern of bone known as regional acceleratory phenomenon (RAP).^[4]

Wilckodontics results in the following: a) An increase in width of alveolar bone,^[5] b) Shorter treatment time,^[6] c) Greater post treatment stability,^[7] d) Decreased apical root resorption.^[8]

Name & Address of Corresponding Author

Dr. R Saranyan Ravi
Professor,
Department of Periodontia,
VMSSDC, Salem,
Tamil Nadu, India.
Email: ravisaranyan@gmail.com

HISTORICAL PERSPECTIVE

Since 1800s, surgical aid was used in orthodontic tooth movements (OTM). Bryan (1893) first described the corticotomy –facilitated tooth movement, in a text book called ‘Orthodontia’: Malposition of the Human Teeth, Its Prevention and Remedy.^[9]

Later Heinrick kole (1959) described the combined radicular corticotomy or supra apical osteotomy technique.^[10] This technique is being adopted or modified by most of the practitioners for the current corticotomy procedures. The term bony block arose from kole’s work, to describe the suspected mode of movement after corticotomy surgery. Rapid tooth movement was believed to occur with surgical preparation of the alveolus, suggesting that the continuity and thickness of the denser layer of cortical bone offered the most resistance to tooth movement. According to him surgically outlined blocks of bone, retained their structural integrity during healing process. He used removable appliances fitted with adjustable screws with heavy forces and later reported that the major active tooth movements can be accomplished in 6 to 12weeks.Space closing was the main movement described. He used vertical wedge-shaped crestal osteotomies, leaving only a thin layer of bone over the proximal root surfaces of the adjacent teeth. Köle reported that after 6 to 8 months of retention, the corticotomy-facilitated orthodontic cases remained remarkably stable.

Generson et al (1978)^[11], Anholm et al (1986)^[12], Gantes et al (1990)^[13] and Surya (1991)^[14] in their techniques

modified the supra-apical horizontal cut with labial and lingual corticotomy cuts.

In the early 1990s, Dr Wilcko's, using computed tomography, discovered that reduced mineralization of the alveolar bone was the reason behind the rapid tooth movement following corticotomies. They used their knowledge of corticotomy and their observations of RAP to develop their patented periodontally accelerated osteogenic orthodontics (PAOO) technique in 1995. It is based on a treatment method combining selective alveolar decortication, alveolar augmentation and orthodontic treatment. This method of PAOO is patented as "Wilckodontics". Based on the emerging concepts of Wilcko brothers.^[15,16] Yaffe et al^[17] described a similar procedure in periodontal literature. Recently, William Wilcko and Thomas Wilcko have demonstrated rapid orthodontic tooth movement following selective labial and lingual decortication of alveolar bone in the area of desired tooth movement using a technique called accelerated osteogenic orthodontic tooth movement (AOTM) [Figures 1&2].



Fig. 1: William Wilcko

Fig. 2: Thomas Wilcko

BIO-MECHANICS OF WILCKODONTICS

Regional Acceleratory Phenomenon (RAP)

Herald Frost collectively mentioned the events in physiologic healing and called it as "The Regional acceleratory phenomenon" (RAP)^[18,19]. He was the first to find that surgical wounding of osseous tissues resulted in tissue stimuli adjacent to the site of the injury, which results in faster than normal regional regeneration and remodeling process.^[20] RAP causes bone to heal 10-50 times faster. Following surgical injury in human long bone, RAP begins within a few hours, maximum action is usually reached in 1-2 months and usually may take 6-24 months to complete.^[19] Application of orthodontic force can stimulate or trigger mild RAP activity. RAP can be maximized when selective decortication is combined with tooth movement. Wilcko brothers (2001) revised the bony

block technique and attempted two cases of crowding with selective decortication. To sum up, surgically assisted periodontally driven orthodontic treatment is a combination of bone regeneration (somatic cell therapy) and gene therapy (alteration of gene expression). Tissue engineering principles and periodontal regeneration in PAOO, is an entirely new technology in dentofacial orthopedics, to obtain a steady state tissue response to accomplish orthodontic tissue movements rapidly [Figure 3].

Clinical Considerations

Clinical indications according to Wilcko brothers, a) to accelerate or fasten corrective orthodontic treatment, b) to facilitate the mechanically challenging orthodontic movements, c) to facilitate correction of moderate to severe skeletal malocclusions.^[21]

PAOO is contraindicated in certain conditions like a) in patients with active periodontal disease, b) inadequately performed endodontic treatment, c) patients with history of prolonged corticosteroid usage, d) Patients on medication which interfere bone metabolism such as bisphosphonates or non-steroidal anti-inflammatory drugs (NSAIDs).

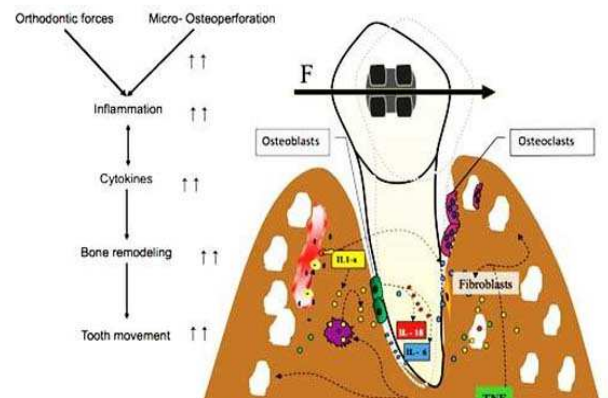


Figure 3: Regional acceleratory phenomenon

Case Selection and Treatment Planning

In PAOO, case selection and treatment plan are combined effort of the orthodontist and periodontal surgeon. Orthodontist determines the OTM plan, arch segment to contract or expand and anchorage units. The periodontal surgeon considers the periodontal status, muco-gingival conditions and esthetic needs of the patient.^[22] To take full advantage of RAP procedure the orthodontic bracket bonding and activation of arch wire should be performed within two weeks. Anchorage must be established before PAOO procedure in class 2 mal-occlusions. Adjustments should be done at 2 week interval, during active orthodontic treatment period to decrease the risk of re-calcification in mid treatment. Appropriate motivation for proper maintenance of oral hygiene should be given.

Muco-gingival surgeries if required should be done before bracketing.

Surgical Technique

1) Flap design: Full access to the surgical site is the ideal requisite of flap design. Mesial and distal extension is decided and vertical releasing incisions are avoided. Gingival collars are preserved on both palatal and buccal gingiva. Full thickness flap is elevated towards the coronal aspect and partial thickness towards the apical portion to avoid tension at the time of closure. The ideal design should allow full accessibility to the corticotomy site, provide full coverage for graft material and enhance aesthetics wherever required.^[22]

2) Decortication: Corticotomies are done in mid interdental areas, using no 2 carbide bur which are connected with circular cuts. Corticotomies^[23] should be performed on both labial and palatal aspects of alveolar bone. No mobile segments of bone should be created to initiate RAP. Instruments used are commonly hand piece or a piezosurgical knife. Care should be taken on all anatomic structures and one has to follow all general principles of surgery.^[22]

3) Bone grafts: Commonly de-proteinized bovine bone, decalcified free-dried bone allograft and autogenous bone grafts are used solely or in combination within or with platelet concentrations such as platelet rich plasma in corticotomy areas. Around 0.25 to 0.5 ml of graft material is required per teeth. Barrier membrane use is usually discouraged.^[22]

4) Modifications in grafting: In certain cases due to thin gingival biotype as well as thin cortical plate of bone, exposure of root surface can be seen in some cases. In such cases use of autogeneous soft grafts such as connective tissue grafting (gold standard) can be included under full thickness flap. Connective tissue graft can be harvested from palate. Platelet rich plasma, platelet rich fibrin, and growth factors can also be included under the flap along with bone grafts to increase the stability of the graft.^[22]

5) Primary closure: For predictable bone augmentation, flap should be closed without excessive tension. Flap is usually sutured at the mid line in the interproximal areas followed by other areas. Suture material of choice is non resorbable sutures. Suture removal is carried out usually in 7-14 days postoperatively. Periodontal pack is not usually preferred [Figure 4].

6) Patient management: The time taken for surgery may vary according to the individual cases. Complicated bimaxillary cases may take several hours which may demand sedation of the patient. Antibiotics, analgesics and NSAIDS can be given for patient comfort and clinical healing enhancement. NSAIDS should not be given for long term as they are considered to be interfering with RAP. Narcotic pain killers can be prescribed for a week. Common post-surgical complications include pain, edema and ecchymosis. Ice packs can be applied for suppressing

swelling. Chlorhexidine mouthwash can also be prescribed.

7) Orthodontic adjustments after PAOO surgery:^[24] Orthodontist adjust the braces every 2 weeks, after complete recovery from surgical procedure. Completion can take 3-9 months depending up on the case. A retainer will have to be used for at least 6 months. According to the patient selection a metal or ceramic bracket can be used.

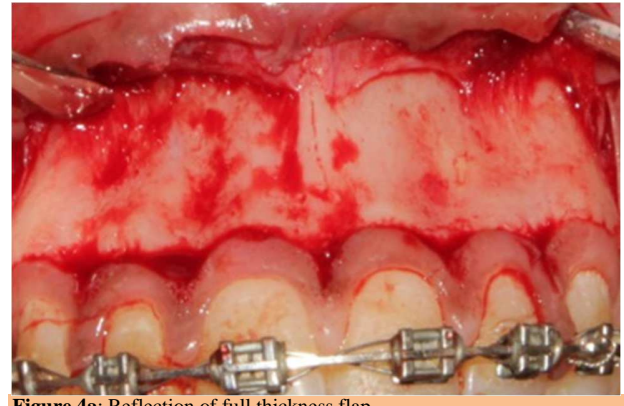

Figure 4a: Reflection of full thickness flap

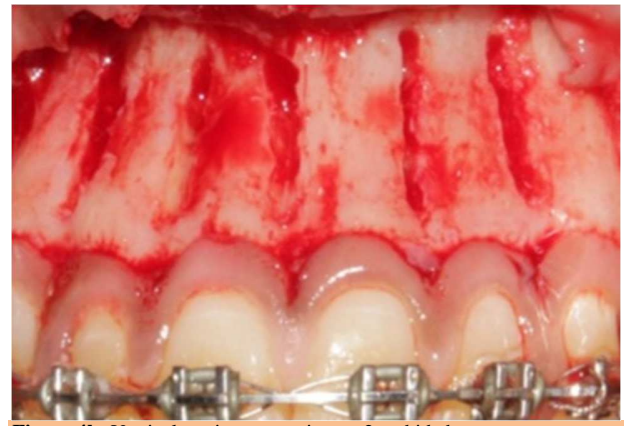

Figure 4b: Vertical corticotomy using no 2 carbide bur

8) Patient age consideration for PAOO: As long as they have healthy periodontium, age is not a contraindication for patient selection. The technique has been done on patients as young as 11 years and on geriatric patients as old as 77 (as dental implant or device preparations) according to Wilcko brothers.

9) Significant clinical applications: PAOO has been proved to be clinically effective in several situations like crowding.^[25] canine retraction after premolar extraction, impacted tooth eruption, facilitate orthodontic expansion, open bite correction with molar intrusion, post orthodontic stability, class I malocclusion with moderate to severe crowding, class II malocclusions, mild class III malocclusions, severe bi-maxillary protrusion, treatment of cleft lip and palate cases.

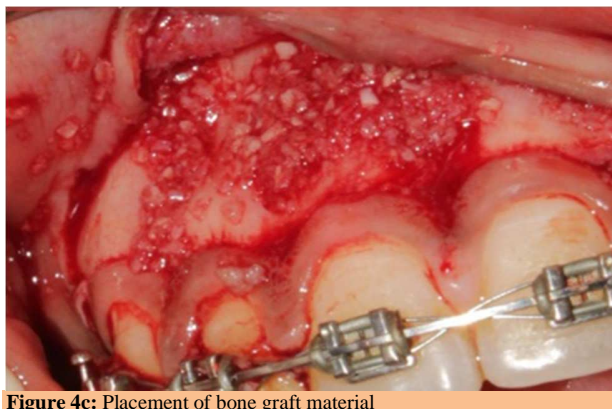


Figure 4c: Placement of bone graft material

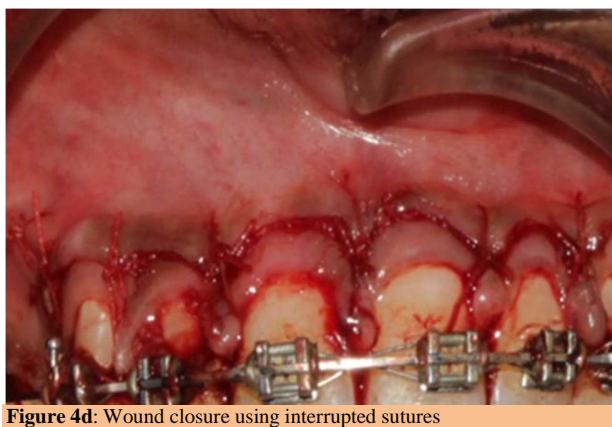


Figure 4d: Wound closure using interrupted sutures

10) Modification of CAO procedure:

A) Compression osteogenesis (CO): Procedures like molar intrusion may be designated with CO instead of CAO (corticotomy accelerated osteogenesis), as the medullary bone and overlying mucosa supports the tooth-bone block. The CO concept is similar to CAO concept, but uses corticotomy instead of corticotomy. CAO causes movement of teeth in the weakened alveolar bone but CO causes movement of bone block along with teeth. Kanno et al, used CO procedure to treat severe open bite case and obtained desired results in 6 months by moving the upper posterior bone tooth segments 7mm in a posterior direction and using anchor plates and elastics after 3 weeks of surgery.^[26]

B) Alveolar corticotomies (ACS): The incision must pierce the cortical layer and should penetrate minimally into bone marrow,^[27] in ACS. Thus ACS is defined as a surgical intervention limited to the cortical portion of the alveolar bone. In osteotomies, considerable amount of both cortical and trabecular bone material is removed.

11) Novel approaches in PAOO:

A) Lasers: Flapless corticotomy assisted by lasers reduces treatment time and damage to the periodontium, as this is a non-invasive procedure. Orthodontic tooth movement is

enhanced by cortical bone layer reduction. Erbium, Chromium doped Yttrium Scandium Gallium Garnet (Er-Cr: YSGG) laser irradiation, without surgical flap reflection^[28] are commonly used lasers.

B) Piezo-electrics: Dibart et al described the tunneling approach using piezoelectric bone cuts to solve a mild crowding case within 17 weeks.^[29] Here several vertical incisions are placed on the attached gingiva using piezoelectric vertical corticotomies. Bone graft were placed using tunneling approach.^[29]

C. Monocortical tooth dislocation and ligament distraction (MTDLD) technique; two different dental movements work simultaneously and separately on opposite root surface in MTDLD technique. Using a piezosurgical micro saw, vertical and horizontal microsurgical corticotomies are performed around each tooth root to eliminate cortical bone resistance, on the root surface corresponding to the direction of movement. Rapid dislocation of the root and cortical bone is produced by immediate application of strong biomechanical forces. The dislocation force produces rapid distraction of periodontal ligament fibers on the root surface opposite to the direction of movement.^[30]

Pros and Cons of PAOO Surgery

Pros: Less time than traditional orthodontic procedures^[31], less likelihood of root resorption, history of relapse is very low, less need for appliances and headgear (depending on the case), the technique has its roots in proven orthopedic research and treatments, both metal and ceramic brackets can be used.

Cons: Expensive procedure, mildly invasive surgical procedure and like all surgeries, it has risk of some pain, swelling and the possibility of infection, patients who take NSAIDs on a regular basis or have other chronic health problems cannot be treated with this technique. NSAIDs lead to prostaglandin inhibition resulting in reduced osteoclastic activity thus disturbing bone remodeling.^[14], patients on long term steroid therapy due to the presence of devitalized areas of bone, it does not lend itself to severe class III malocclusion cases.

CONCLUSION

Conventional orthodontic treatment typically takes between 18-24 months, the relatively new procedure wilckodontics takes only 3-9 months without compromising the treatment quality. PAOO has shown to significantly reduce the treatment time, better post orthodontic stability, reduce the incidence of root resorption and increase the alveolar bone thickness by the inclusion of bone graft which results in more stable periodontium. It also decreases the need for extraction. But long term treatment outcomes are unavailable as it is

relatively new procedure. With proper synergy of orthodontist and periodontist, successful treatment can be achieved.

REFERENCES

- 1) Little RM. Stability and relapse of dental arch alignment In Burstone CJ, Nanda R (eds): Retention and stability in Orthodontics. Philadelphia, Saunders, 1996, pp 213-27.
- 2) M.T. Wilcko, W.M. Wilcko, and N.F. Bissada. An evidence-based analysis of periodontally accelerated orthodontic and osteogenic techniques: a synthesis of scientific perspectives. *Seminars in Orthodontics*,2008;14(4):305-316.
- 3) Wilcko WM, Wilcko MT, Bouquot JE, et al: Rapid orthodontics with alveolar reshaping: Two case reports of decrowding. *Int J Periodontics Restorative Dent*,2001;21:9.
- 4) Pham-Nguyen K: Micro-CT analysis of osteopenia following selective alveolar decortication and tooth movement [master's thesis]. Boston, MA, Boston University,2006.
- 5) Twaddle BA, Ferguson DJ, Wilcko WM, et al: Dento-alveolar bone density changes following corticotomy-facilitated orthodontics. *J Dent Res* 2002;80:301.
- 6) Hajji SS: The influence of the accelerated osteogenic response on mandibular decrowding. *J Dent Res*,2001;30:180.
- 7) Nazarov AD, Ferguson DJ, Wilcko WM. Improved orthodontic retention following corticotomy using ABO Objective Grading System. *J Dent Res* 2004;83:26-44.
- 8) Machado IM, Ferguson DJ, Wilcko WM. Reabsorción radicular después del tratamiento ortodóncico con o sin corticotomía alveolar. *Rev Venez Ortod* 2002;19:647.
- 9) Nowzari H, Yorita FK, Chang HC. Periodontally accelerated osteogenic orthodontics combined with autogenous bone grafting. *Compend Contin Educ Dent* 2008;29(4):200-6.
- 10) Kole H. Surgical operations on the alveolar ridge to correct occlusal abnormalities. *Oral Surg Oral Med Oral Pathol*. 1959;12(5):515-29.
- 11) Generson RM, Porter JM, Zell A. Combined surgical and orthodontic management of anterior open bite using corticotomy. *J Oral Surg* 1978;34:216.
- 12) Anholm M, Crites D, Hoff R. Corticotomy-facilitated orthodontics. *Calif Dent Assoc J* 1986;7:8.
- 13) Gantes B, Rathbun E, Anholm M: Effects on the periodontium following corticotomy-facilitated orthodontics. Case reports. *J Periodontol* 1990;61:234.
- 14) Suya H. Corticotomy in orthodontics, in Hösl E, Baldauf A (eds): *Mechanical and Biological Basics in Orthodontic Therapy*. Heidelberg, Hütlig Buch, 1991, pp 207-226
- 15) Wilcko WM, Wilcko MT, Bouquot JE, et al. Rapid orthodontics with alveolar reshaping: Two case reports of decrowding. *Int J Periodontics Restorative Dent* 2001;21:9-19.
- 16) Wilcko WM, Ferguson DJ, Bouquot JE. Rapid orthodontic decrowding with alveolar augmentation: Case report. *World J Orthodont* 2003;4:197-505.
- 17) Yaffe A, Fine N, Binderman I. Regional accelerated phenomenon in the mandible following muco-periosteal flap surgery. *J Periodontal* 1994; 65:79-83.
- 18) Frost MH. The biology of fracture healing: An overview for clinicians Part II. *Clin Ortho*. 1989;248:294-309.
- 19) Frost HM. The regional acceleratory phenomenon: a review. *Henry Ford Hosp Med J*. 1983;31:3-9.
- 20) Schilling T, Müller M, Minne HW, Ziegler R. Influence of inflammation-mediated osteopenia on the regional acceleratory phenomenon and the systemic acceleratory phenomenon during healing of a bone defect in the rat. *Calcif Tissue Int*. 1998;63:160-6.
- 21) Einy S, Horwitz J, Aizenbud D. Wilckodontics--an alternative adult orthodontic treatment method: rationale and application. *Alpha Omegan*. 2011;104(3):102-11.
- 22) Murphy KG, Wilcko MT, Wilcko WM, Ferguson DJ. Periodontal accelerated osteogenic orthodontics: a description of the surgical technique. *J Oral Maxillofacial Surg*. 2009;67(10):2160-6.
- 23) Kim SH, Kim I, Jeong DM, Chung KR, Zadeh H. Corticotomy-assisted de-compensation for augmentation of the mandibular anterior ridge. *Am J Orthod Dentofacial Orthop*. 2011;140(5):720-31.
- 24) Binderman I, Gadban N, Bahar H, Herman A, Yaffe A. Commentary on Periodontally accelerated osteogenic orthodontics [PAOO]-a clinical dilemma. *International Orthodontics* 2010;43:1-10.
- 25) Aljhani AS, Zawawi KH. Non-extraction Treatment of Severe Crowding with the Aid of Corticotomy-Assisted Orthodontics. *Case Rep Dent*, 2012;69:452-7.
- 26) Kanno T, Mitsugi M, Furuki Y, Kozato S, Ayasaka N, Mori H. Corticotomy and compression osteogenesis in the posterior maxilla for treating severe anterior open bite. *Int J Oral Maxillofac Surg*. 2007;36:354-7.
- 27) Chung KR, Kim SH, Lee BS. Speedy surgical-orthodontic treatment with temporary anchorage devices as an alternative to orthognathic surgery. *Am J Orthod Dentofacial Orthop*. 2009;139:787-98.
- 28) MassoudSeifi, FarnazYounessian, Nazila Ameli. The innovated laser assisted flapless corticotomy to enhance orthodontic tooth movement. *J Lasers in Med Sci*. 2012;3:1-12.
- 29) Dibart S, Sebaoun JD, Surmenian J. Piezocision: a minimally invasive, periodontally accelerated orthodontic tooth movement procedure. *Compend Contin Educ Dent*. 2009;30:342-50.
- 30) TomasoVercellotti, Andrea Podesta. Orthodontic Microsurgery: A new surgically guided technique for dental movement. *Int J Periodontics Restorative Dent*. 2007;27:325-31.
- 31) Yezdani AA. Accelerated orthodontics with alveolar decortication and augmentation: A case report. *Orthodontics (Chic.)*. 2012;13(1):146-55.

How to cite this article: Nisha N, Ravi RS, Anthraper AJ, Shewale A, Sainu R, Kurian SR. Wilckodontics- A Magical Wand for Rapid Success-A Review. *Ann. Int. Med. Den. Res*. 2015;1(3):110-14.

Source of Support: Nil, **Conflict of Interest:** None declared