

Superficial Ulnar Artery Rerouted with Embryological Basis- A Case Report.

Shikky Garg¹, Anjali Gupta², Anshu Gupta²

¹Associate Professor, Department of Anatomy, S N Medical College, Agra, India.

²Lecturer, Department of Anatomy, S N Medical College, Agra, India.

ABSTRACT

Variations in course of the arteries are well documented. Knowledge of the variation of the arterial system is important during vascular and reconstructive surgeries, in the evaluation of angiographic images. During routine anatomical dissection of upper limb, of adult male cadaver of 55 years in Department of anatomy, SNMC, Agra, we came across a variant origin of the ulnar artery, instead of terminal division of brachial artery it arose from the brachial artery at its lower 1/3 part, also it followed a superficial course. Brachial artery in the cubital fossa divided into radial artery and common interosseous artery, also the anterior and posterior ulnar recurrent branches arose from the common interosseous branch instead of ulnar artery. Knowledge of this variation is important for anatomist, embryologist, radiologists keep pace with new emerging variations, also for orthopaedicians, surgeons for planning appropriately operative procedures involving this region.

Keywords: superficial ulnar artery, superficial brachial artery, brachial artery, common interosseous artery, anterior and post ulnar recurrent artery.

INTRODUCTION

Brachial artery is the main artery of the arm. It is a continuation of axillary artery at lower border of the teres major muscle; it usually terminates in cubital fossa at the neck of radius by dividing into the deep ulnar artery and superficial radial artery.

The radial artery runs along the lateral part of forearm along with the superficial branch of radial N. The ulnar artery passes deep to superficial flexors of the forearm muscles here it is separated from ulnar nerve by a considerable distance. From lower 2/3d of forearm the artery descend vertically and undergo a superficial course b/w flexor carpi ulnaris medially & flexor digitorum superficialis laterally. Ulnar nerve lies medial to the ulnar artery. The ulnar artery along with ulnar nerve on medial side crosses the flexor retinaculum and enter palm common interosseous artery is short branch of ulnar artery passes back to proximal border of interosseous membrane & divide into anterior & posterior interosseous arteries.

Name & Address of Corresponding Author

Dr Shikky Garg
Associate Professor,
Department of Anatomy,
S N Medical College,
Agra, India.
E mail: deepakshikky@gmail.com

The sup ulnar artery is a variation of ulnar artery. The term superficial ulnar artery is given when it arises from axillary or brachial arteries and course over superficial muscles of the forearm and later joins with ulnar artery or sometimes may replace it.^[1,2]

CASE REPORT

During routine anatomical dissection of upper limb of adult male cadaver of 55 yrs in department of anatomy sync Agra, we came across the variant origin of ulnar artery arising from the brachial artery from its lower 1/3rd part, initially we mistook it for inferior ulnar collateral artery, but following its course we found it to be ulnar artery as it accompanied the ulnar nerve in the lower part of the forearm, then entered the hand along with the ulnar nerve.

Ulnar artery originated from brachial in distal part of the arm. it descended on the lateral side up to the cubital fossa and crossed from the lateral to medial side superficial to Median nerve [Figure 1] to run on medial aspect of forearm accompanying the ulnar nerve in lower 1/3rd part of forearm. [Figure 2].

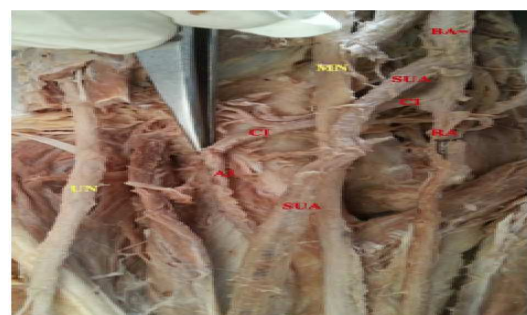

Figure 1: Origin of SUA [superficial ulnar artery] from BA [brachial artery].

MN=Median nerve; UN=ulnar nerve; RA=Radial artery; CI=Common interosseous artery; AI=Anterior interosseous artery.



Figure 2: UN accompanying SUA in lower part of forearm.

In the lower part of the forearm ulnar artery lies superficially in b/w Flexor Carpi Ulnaris and Flexor digitorum superficialis, at the wrist it coursed superficial to flexor retinaculum to enter the palm along with the ulnar nerve. Throughout its course it was superficial and gave no branch

The brachial artery had usual course till the intercondylar line. Just below intercondylar line the brachial artery divided into 2 arteries a superficial radial artery as this followed the same course as radial artery, [Figure 1, marked by al pin]

While 2nd branch was a large common interosseous branch that terminated in anterior & posterior interosseous branches, also this branch gave 2 branches, anterior [AUR] and post ulnar recurrent [PUR] as they took part in anastomosis around the medial condyle of humerus anteriorly and posterior respectively. Anterior ulnar recurrent interestingly ran a transverse course winded round post ulnar recurrent from below to upward direction and then ascended in front of medial condyle of humerus to take part in anastomosis around elbow it. [Figure 3] Post ulnar recurrent due to winding of anterior ulnar recurrent showed a small erect course then turned medially to run on posterior aspect of medial condyle interestingly a transverse channel, very minute existed between two, this was cut to clarify the region for a better view. The site of origin of anomalous arteries in the arm is determined with reference to the intercondylar line of the humerus. The bifurcation of brachial artery proximal to this line is considered a variation.^[4] In our case bifurcation has been just about intercondylar line.^[4] Common interosseous terminated in anterior and post interosseous artery. Bifurcation of the brachial artery into radial and common interosseous arteries may be correlated with the sprouting of posterior interosseous artery from the axis artery distal to the sprouting of the radial artery in the cubital fossa. And, the portion between radial and posterior interosseous arteries becomes common interosseous artery and the remaining part of axis artery becomes anterior interosseous artery.^[5] In right upper limb, arterial pattern was normal.

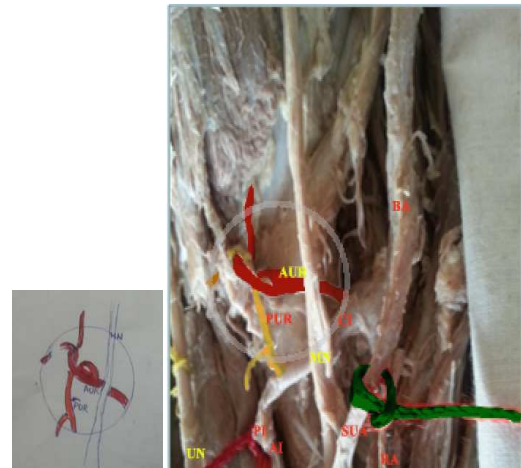

Figure 3: AUR [Anterior ulnar recurrent winding around PUR [Posterior ulnar recurrent] from below upwards. [As seen in inset].

DISCUSSION

Knowledge of origin, course and distribution of any artery is important as it has clinical implications. A basic law of vascular anatomy is that the only thing, which remains constant, is its variability. The vascular anatomy is more variation in the living than in the dead and it varies among people living in different countries. Some arteries have more variations than others.^[6]

The incidence of an abnormality in the arterial anatomy of the upper limb varies from 18.53% to 20%.^[7]

Sup ulnar artery incidence ranges from 0.75 to 3.3%.^[8]

Since a superficial ulnar artery is actually not very rare, there is a fair chance that clinicians may encounter this anomaly. Therefore, one should always keep in mind this anatomic variation and try to detect it before any technical procedure in the upper limb. Owing to its surgical importance, variations of the ulnar artery merit description.

Such an artery may present a superficial pulse and a hazard to venipuncture and lead to intra-arterial injection or ligature instead of vein in the cubital fossa.^[9]

Pulakunta et al, have reported variation of co-existence of superficial ulnar artery and aneurysm of deep palmar arch in hand.^[10]

This is also important in patients who require surgical intervention because of a thrombosed forearm artery and poor collateral circulation. When treating a rupture of the distal bicipital tendon, an orthopaedic surgeon should be aware of this atypical blood vessel.^[11]

The presence of an SUA need not always be regarded as an adverse feature, as its presence may allow plastic surgeons to use it in a reconstructive ulnar flap.^[11]

The superficial ulnar artery may be useful in arterial grafts and plastic surgeries

The importance of this variable is also growing with the increasing use of radial arteries as conduits in coronary bypass.^[12]

Its clinical importance should not be underestimated as several cases of intra-arterial injection of drugs and subsequent amputations have been reported,^[13,14] therefore Knowledge of this variation is important, not only for surgeons but also for other medical and nursing staff because they commonly perform intravascular cancellations.

Embryological Basis

Following the classical description of Singer E and Arey LB, as quoted earlier by different authors to explain such anomalous vascular pattern in their case reports, it is evident that initially in the embryonic life a vascular network exists which undergoes sequential appearance and disappearance establishing the axial artery of the limb. The arterial variation takes place when the vessel which is to get obliterated either persists or the one to persist gets obliterated. Even the incomplete development of the vessel or fusions and absorption of their parts in different combinations may lead to the unusual course.^[15]

According to Singer^[16] and Arey LB^[17] at first (stage I) the lateral branch of a seventh inter-segmental artery, i.e., the subclavian artery extends up to the wrist as the axis artery of upper limb, where it terminates by dividing into terminal branches for the fingers forming a capillary plexus. The proximal portion of it forms axillary and brachial arteries respectively, whereas distal portion persists as the 'anterior interosseous artery' of forearm.

Then (stage II) a 'median artery' arises from the anterior interosseous artery, grows along the median nerve to communicate with palmar capillary plexus to feed it. By this time, the anterior interosseous artery undergoes regression.

After it (stage III) the 'ulnar artery' arises from brachial artery in forearm and unites distally with the existing median artery to form superficial palmar arch.

Later (stage IV) a 'superficial brachial artery' develops in the axillary region from the axial trunk and traverses the medial surface of the arm, runs diagonally from the ulnar to the radial side of the forearm to the posterior surface of the wrist to divide over the carpus into digital branches.

Finally, (stage V) three successive changes occur to chose the final arterial tree as:

1. The superficial brachial artery gives off a distal branch anastomosing with the superficial palmar arch formed already and the 'median artery' regresses to a small slender vessel, familiar in adult life as *arteria nervi mediana*.

2. At the elbow an anastomotic branch develops between the main trunk of brachial artery and existent superficial brachial artery, which later enlarges to form the 'radial artery' with the distal portion of the superficial brachial artery.

3. Proximal portion of the superficial brachial artery atrophies correspondingly.^[4]

The unusual path chosen by the arterial arcade, here, in their sequential appearance and disappearance of the arteries of the upper limb, results finally the arterial variation, which can be explained here as:

Variation in third stage: From the trunk of brachial artery instead of the ulnar artery being originated, the radial artery takes its origin.

Variation in fourth stage: The superficial brachial artery instead of its development to lateral side originated in the medial side of arm to join the palmar capillary plexus; and appeared as the ulnar artery in adult life.

Variation of final stage: The scheduled anastomosing branch near the elbow developed, resulting in communication of brachial with ulnar artery in its lower 1/3 rd part

The proximal portion of superficial brachial artery regressed while its distal portion with anastomosing branch formed sup ulnar artery Secondly, the 'median artery regressed,

This high-up origin of ulnar artery was previously noted in earlier researches done by Pattanaik VVG et al.,^[3] Satyanarana N et al.,^[18] Roy H et al.,^[19] Banerjee A et al.,^[20] Dave MR et al.,^[5] in their case studies, where they have explained it in light of similar ontogenic error either in the form of aberrant sprouts of axis artery or regression of those channels which should have been persistent and persistence of those channels which should have been regressed.

Keeping in view chaos an superficial ulnar artery can cause if present and mistaken for vein it should be culcated in medical practice to palpate superficial pulse over the canulation site before any procedure is carried out on upper limb by anybody be it medical professional or any medical staff ,this will probably minimize the risk of damaging an artery and subsequent bleeding.

CONCLUSION

Superficial ulnar artery presence is not very rare therefore one should always keep in mind this variation and try to detect it before any technical procedure is carried out in upper limb.

Knowledge of this variation is important for anatomist, embryologist radiologist to keep pace with new emerging variations, also for orthopaedicians, surgeons for planning appropriately operative procedures involving this region.

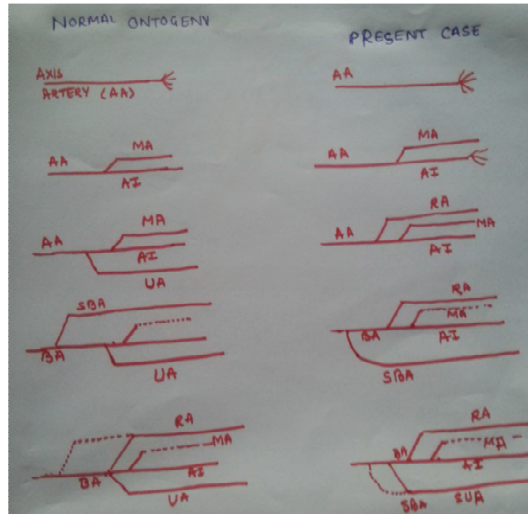


Figure 3: Ontogenic stages of formation of upper limb arteries & the present case.

[AA=Axis artery; MA=Median artery; AI=Anterior interosseous artery; RA=Radial artery; UA=Ulnar artery; BA=Brachial artery; SA=Superficial brachial artery; BA=Brachial artery]

REFERENCES

1. Nakatani T, Tanaka S, Mizukami S, Shiraiishi Y, Nakamura T. The superficial ulnar artery originating from the axillary artery. *Ann Anat.* 1996;178:277-279.
2. Lippert H, Pabst R. Arterial Variations in Man. Munich Bergmann. 1985;66-73.
3. Patnaik VVG, Kalsey G, Singla RK. Bifurcation of axillary Artery in its 3rd part-a case report. *J Anat. Soc India.* 2001;50:166-9.
4. Karlson S. Niechajev. *Acta Radiologic Diagnosis.* 1982;23:34-8.
5. Dave MR, Yagain VK, Adadkat S. Unilateral high origin of ulnar artery with variant bifurcation of brachial artery: a case report. *Int J Anat Var.* 2012;5:65-7.
6. Uzun A, Seelig Jr LL. The anastomotic artery connecting the axillary or brachial artery to one of the forearm arteries. *Folia Morphol.* 2000;59(3):217-22.
7. Natsis K, Papadopoulou AL, Papatthanasiou E, Nossios G, Paraskevas G, Lazaridis N. Study of two cases of high-origin radial artery in humans. *Eur J Anat.* 2009;13(2):97-103.
8. Muller E. Beitrage zur Morphologie des Gefässsystems. I. Die Armarterien des Menschen. *Anat Hefte.* 1903;22:377-575.
9. Allan FD. Arteries of the extremities. *In: Essentials of Human Embryology.* 2nd ed. London: Oxford; 1969. 97[4]
10. Pulakunta T, Potu BK, Vollala VR, Goranta CR, Thomas H. coexistence superficial ulnar artery & aneurysm of the deep palmar arch in the hand. *Bratisl Leklisty.* 2009;110:738-739
11. Venkata RV, Raghu J, Simmi S. High Origin of An Ulnar Artery-Development and Surgical Significance. *Chang Gung Med J.* 2011;34(6 Suppl):39-42.
12. Joseph J, Ranjit D, Jatin D. Superficial ulnar artery. *Eur J Cardiothorac Surg.* 2005;28:495-6. 2nd ed. London: Oxford, 1969:97.
13. Ohana E, Sheiner E, Gurman GM. Accidental intra-arterial injection of propofol. *Eur J Anaesthesiol* 1999;16:569-70.
14. Goldberg I, Bahar A, Yosipovitch Z. Gangrene of upper extremity following intra-arterial injection of drugs. A case

report and review of the literature. *Clin Orthop Relat Res.* 1984;188:223-9.

15. Collins P, Williams P, Bannister L, Collins P, Dyson M, Dussek J, Ferguson M. Arteries of the limb. *Embryonic circulation. Section: Embryology and development, Gray's Anatomy; The Anatomical basis of Medicine and Surgery,* Edinburgh. Churchill Livingstone. 1995; 38: 319.
16. Singer E. Embryological patterns persisting in the arteries of the arm. *Anat Rec.* 1933;55:406-13.
17. Arey LB. 7th Ed. Philadelphia: W.B. Saunders; *Developmental Anatomy. A textbook and laboratory manual embryology;* 1965. pp. 358-9.).
18. Satyanarayana N, Sunitha P, Munvar MS, Satya P VD. Brachial artery with high up division with its embryological basis and clinical significance. *Int J Anat Var.* 2010;3:56-8.
19. Roy H, Pradhan PP, Deb S. A rare coexistence of axillo-brachial neurovascular variations with embryological review. *Int J Anat Var.* 2011;4:15-8.
20. Banerjee A, Roy H, Tapadar A, Kumar IA, Dasgupta A. Prevalance Of Double Brachial Arteris- Cadaveric Study From Two Distant Zones Of India. *Nat J Basic Med Sciences.* 2012;Vol 3(1):10-3.

How to cite this article: Garg S, Gupta A, Gupta A. Superficial Ulnar Artery Rerouted with Embryological Basis- A Case Report. *Ann. Int. Med. Den. Res.* 2016;2(1):67-70.

Source of Support: Nil, **Conflict of Interest:** None declared