

A Study of Clinical Outcome of Precontoured Plate & Screw Fixation in Fracture Midshaft Clavicle.

Abhijit Ghosh¹, Soumya Banerjee², Sudipta Dasgupta³, Rajatabha Biswas², Samiran Dey², Anup Barman²

¹Assistant Professor, Department Of Orthopaedics, Burdwan Medical College, West Bengal, India.

²Junior Resident, Department Of Orthopaedics, Burdwan Medical College, West Bengal, India.

³Associate Professor, Department Of Orthopaedics, Burdwan Medical College, West Bengal, India.

Received: May 2018

Accepted: June 2018

Copyright: © the author(s), publisher. It is an open-access article distributed under the terms of the Creative Commons Attribution Non-Commercial License, which permits unrestricted non-commercial use, distribution, and reproduction in any medium, provided the original work is properly cited.

ABSTRACT

Background: This prospective study was done to evaluate the effectiveness of implants i.e., anatomical precontoured plate in treatment of displaced midshaft clavicular fractures. **Methods:** Thirty patients between 18 and 60 years of age were included in this study. They were treated by fixation with anatomically precontoured plate and functional outcome was assessed. Clinical and radiological assessments were performed at regular intervals. Outcomes and complications of over 1.5 year of follow-up time were compared. **Results:** Range of motion was well maintained in all the patients. Constant score was excellent in 26 patients (87%) good in 2 patients (6.5%) and fair in 2 patients (6.5%). No patients had a poor result on constant scoring. The mean time to union was 5.8 months. **Conclusion:** In this prospective cohort study, primary open reduction and internal plate fixation of acute displaced midshaft clavicular fractures resulted in improved outcomes and a decreased rate of nonunion and symptomatic malunion.

Keywords: Displaced midshaft clavicle fractures/Anatomical precontoured plating.

INTRODUCTION

Clavicle fractures are common injuries accounting for 5–10% of all fractures. Around 85% of clavicle fractures involve the midshaft and over half of these fractures are displaced.^[1] The average age of patients sustaining a midshaft clavicular fracture is 33 years; 70% of the patients are male.^[2] Several fixation methods have been reported including plate fixation,^[3] intramedullary pin fixation and placement of intramedullary threaded k-wires and elastic intramedullary nails.^[4-6] Indications for surgery include the need for earlier functional mobilization in the patient with an isolated injury, in addition to open fractures, floating shoulders and patients with polytrauma.^[7] In recent times, operative indications includes significant shortening or distraction (>1.5 centimeters),^[8] Plate fixation can provide immediate rigid fixation, helping to facilitate early mobilization.^[9] A biomechanical study shows that plate fixation provides a more rigid stabilization compared to intramedullary fixation and may provide a stronger

construction for early rehabilitation protocols.^[10] In this study we evaluated the functional outcome of fixation of clavicle with anatomically contoured plates.

MATERIALS AND METHODS

We conducted a prospective study to compare outcomes and complications of closed displaced midshaft clavicular fractures treated with precontoured plates. Between January 2017 and June 2018, a total of 30 patients with closed displaced midshaft clavicular fractures were admitted in our hospital. Patients who were included in the study were younger (Between 16 and 60 years of age), Shortening or displacement of over 15 mm and axial malalignment of over 30° with no cortical bone contact.^[13] A fracture in the middle third of the clavicle (A fracture amenable to plate fixation with a minimum of three screws in each proximal and distal fragment), and informed consent (With these indications patients were counselled regarding operative management and those who were willing for surgery were included in the study). Patients were excluded from the study if they had an age of less than sixteen years or greater than sixty years, a fracture in the proximal or distal third of the clavicle, a pathological fracture, an open fracture, a fracture seen more than

Name & Address of Corresponding Author

Dr. Sudipta Dasgupta
Associate Professor,
Department Of Orthopaedics, Burdwan Medical
College, West Bengal, India.

Ghosh et al; Clinical Outcome of Precontoured Plate & Screw Fixation in Fracture Midshaft Clavicle

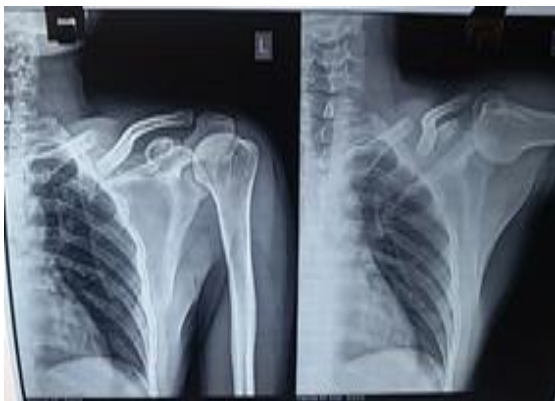twenty-eight days after the injury, an associated neurovascular injury with objective neurological findings on physical examination, a medical contraindication to surgery and/or anesthesia (Such as heart disease, renal failure, or active chemotherapy), and a lack of consent.

Surgical Procedure

Internal fixation was done according to AO principles. After general anesthesia, the patient was positioned in the beach-chair position with a folded sheet under the affected shoulder. A transverse incision was made over the fracture site and dissection was carried out down to the fracture site, followed by careful subperiosteal dissection. The fracture was reduced and held temporarily with bone clamps, and the plate was positioned on the anterior superior surface of the clavicle. In this study, we used a Titanium precontoured 3.5-mm clavicular plate (SMPL). Arm sling support was given to all the patients for 2 weeks postoperatively. Early mobilization was started if pain permitted. Patients were encouraged to resume their normal daily activities after a 4-week postoperative period.

The patients were seen at six weeks and at three, six, and twelve months. Assessment included standardized clinical evaluation and completion of the Constant shoulder score. Both an anteroposterior and a 30° cephalad radiograph was made for each patient. Radiographic union was defined as complete cortical bridging between proximal and distal fragments on both radiographs as determined by the treating surgeon.

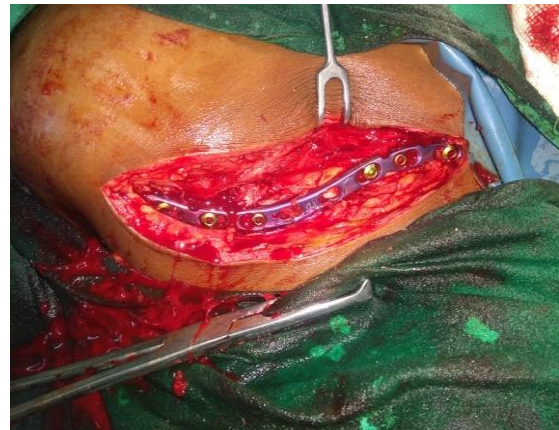Pre-Operative Photo



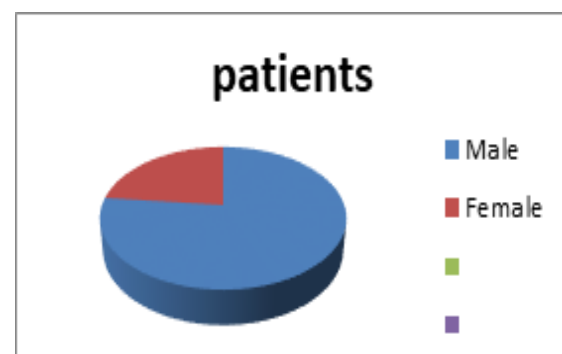
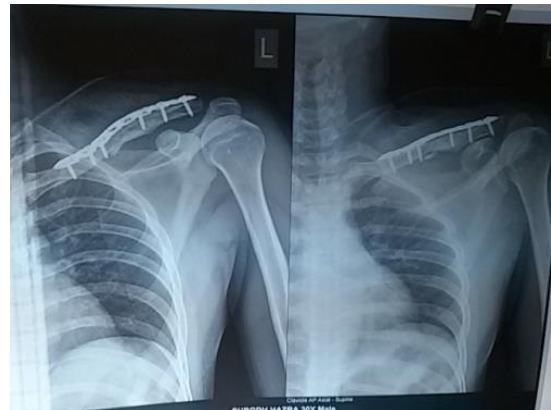RESULTS

Range of motion was well maintained in all the patients, no patient lost >10° of motion in any plane. Constant score was excellent in 26 patients (<11) good in 2 patients (11-20) and fair in 2 patients (21-30). No patients had a poor result (>30) on constant scoring system. The mean time

to union was 6.8 months. No patient developed non-union or mal union. Two cases developed superficial infection (p = 0.62) but infection was controlled by oral antibiotics in all the cases. There was no deep infection. No implant failure occurred. Hypertrophic scar formation was observed in two cases. Two patients had symptomatic hardware prominence. Only one patient had early mechanical failure who underwent revision.



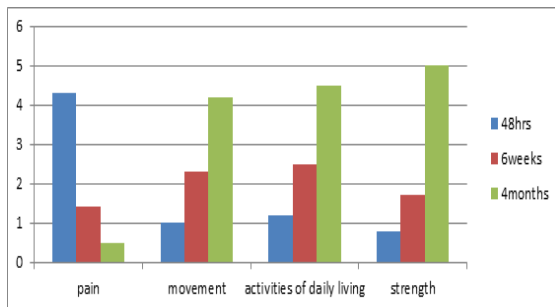
Immediate Post-Operative Photo



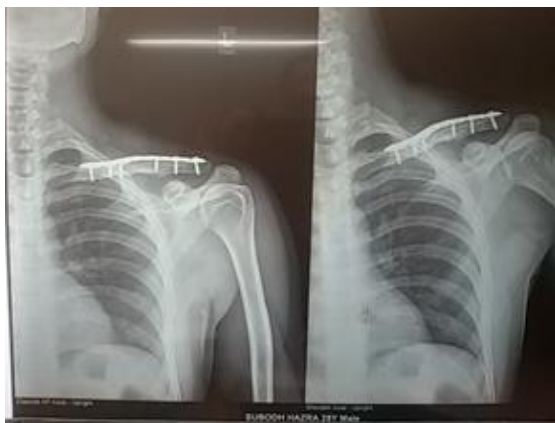Outcome	Results
Surgery time(min)	49.0 (45 -60)
Length of incision(cm)	10.5(9.5-11.2)
Average blood loss(ml)	120.7(110-150)
Hospital stay(days)	7.3 (3 -10)
Union	100%(30 cases)
Time to union(months)	5.8(4-10)

Ghosh et al; Clinical Outcome of Precontoured Plate & Screw Fixation in Fracture Midshaft Clavicle

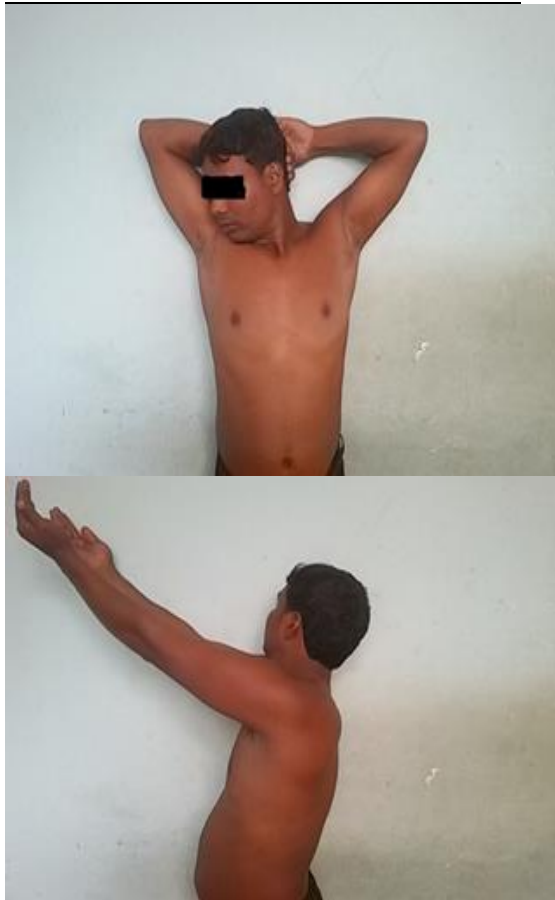DISCUSSION



6 months Follow Up



FUNCTIONAL OUTCOME AT 6 MONTHS



Traditionally, clavicular fractures have been treated nonoperatively. In the 1960s, Neer reported on the non-operative treatment of clavicular fractures. Neer reported nonunion in only three of 2235 patients with middle third fractures treated by closed methods however recent studies have demonstrated that non operative management with figure of eight bandage and sling can cause nonunion and other complications viz malunion and restriction of shoulder movements.^[12] In a study by hill and mcguireeight of the 52 fractures (15%) had developed nonunion, and 16 patients (31%) reported unsatisfactory results.^[13] Robinson et al. described a consecutive series of 868 patients with clavicular fractures, 581 of whom had a midshaft diaphyseal fracture. They found a significantly higher nonunion rate (21%) for the displaced, comminuted midshaft fractures ($p < 0.05$).^[14] Recent studies have also shown that early primary plate fixation of completely displaced midshaft clavicular fractures results in improved patient-oriented outcomes.

Plate fixation can provide immediate rigid fixation, helping to facilitate early mobilization although it has been associated with complications.^[15] A study by Bostman et al reported that complication and reoperation rates may be as high as 43% and 14%, respectively, if hardware removal is considered. Other reported complications include infection, hardware failure, and hypertrophic scarring.^[16] The recent introduction of anatomically contoured clavicle plates may reduce the need for hardware removal.^[17] In our study primary fixation of clavicle was done by anatomically contoured plates. Functional outcome was excellent in 87% of cases. No incidences of non-union or malunion were reported. Hypertrophic scar formation was seen in two cases which was a problem only cosmetically. only one incidence of hardware failure was reported. Our results are comparable with that of another study conducted by Canadian orthopaedic society they reported early union {28.4 weeks in the non-operative group compared with 16.4 weeks in the operative group ($p = 0.001$)} and more malunion in patients treated by non-operative means (9 out of 65 patients).^[18]

CONCLUSION

In conclusion, our study shows that early primary plate fixation of completely displaced midshaft clavicular fractures results in improved patient-oriented outcomes, improved surgeon-oriented outcomes, earlier return to function, and decreased rates of nonunion and malunion.

REFERENCES

1. Postacchini, Franco, et al. "Epidemiology of clavicle fractures." *Journal of Shoulder and Elbow Surgery* 11.5 (2002): 452-456.
2. Khan, LA Kashif, et al. "Fractures of the clavicle." *The Journal of Bone & Joint Surgery* 91.2 (2009): 447-460.
3. Canadian, Orthopaedic Trauma Society. "Non-operative treatment compared with plate fixation of displaced midshaft clavicular fractures. A multicenter, randomized clinical trial." *The Journal of bone and joint surgery. American volume* 89.1 (2007): 1.
4. Chu, Cheng-Mien, Shyu-Jye Wang, and Leou-Chyr Lin. "Fixation of mid-third clavicular fractures with Knowles pins: 78 patients followed for 2-7 years." *Acta Orthopaedica* 73.2 (2002): 134-139.
5. Grassi, Federico A., Maria Serena Tajana, and Fabio D'Angelo. "Management of midclavicular fractures: comparison between nonoperative treatment and open intramedullary fixation in 80 patients." *Journal of Trauma and Acute Care Surgery* 50.6 (2001): 1096-1100.
6. Mueller, Marcus, et al. "Minimally invasive intramedullary nailing of midshaft clavicular fractures using titanium elastic nails." *Journal of Trauma and Acute Care Surgery* 64.6 (2008): 1528-1534.
7. Assobhi, Jamal EH. "Reconstruction plate versus minimal invasive retrograde titanium elastic nail fixation for displaced midclavicular fractures." *Journal of Orthopaedics and Traumatology* 12.4 (2011): 185-192.
8. Zlowodzki, Michael, et al. "Treatment of acute midshaft clavicle fractures: systematic review of 2144 fractures: on behalf of the Evidence-Based Orthopaedic Trauma Working Group." *Journal of orthopaedic trauma* 19.7 (2005): 504-507.
9. Hill, JAMES M., MICHAEL H. McGuire, and LYNN A. Crosby. "Closed treatment of displaced middle-third fractures of the clavicle gives poor results." *Journal of Bone & Joint Surgery, British Volume* 79.4 (1997): 537-538.
10. Golish, S. Raymond, et al. "Journal of Orthopaedic Surgery and Research." *Journal of orthopaedic surgery and research* 3 (2008): 28.
11. Van der Meijden, Olivier A., Trevor R. Gaskill, and Peter J. Millett. "Treatment of clavicle fractures: current concepts review." *Journal of Shoulder and Elbow Surgery* 21.3 (2012): 423-429.
12. Neer, Charles S. "Nonunion of the clavicle." *Journal of the American Medical Association* 172.10 (1960): 1006-1011.
13. Hill, JAMES M., MICHAEL H. McGuire, and LYNN A. Crosby. "Closed treatment of displaced middle-third fractures of the clavicle gives poor results." *Journal of Bone & Joint Surgery, British Volume* 79.4 (1997): 537-538.
14. Robinson, C. Michael, Margaret M. McQueen, and Alison E. Wakefield. "Estimating the risk of nonunion following non-operative treatment of a clavicular fracture." *The Journal of Bone & Joint Surgery* 86.7 (2004): 1359-1365.
15. Mullaji, A. B., and J. B. Jupiter. "Low-contact dynamic compression plating of the clavicle." *Injury* 25.1 (1994): 41-45.
16. Böstman, Ole M., et al. "Clinical biocompatibility and degradation of polylevolute screws in the ankle." *Clinical orthopaedics and related research* 320 (1995): 101-109.
17. Huang J.L., Toogood P., Chen M.R., Wilber J.H., Cooperman D.R. Clavicular anatomy and the applicability of precontoured plates. *J Bone Joint Surg Am.* 2007;89:2260–2265
18. Canadian, Orthopaedic Trauma Society. "Non-operative treatment compared with plate fixation of displaced midshaft clavicular fractures. A multicenter, randomized clinical trial." *The Journal of bone and joint surgery. American volume* 89.1 (2007): 1.

How to cite this article: Ghosh A, Banerjee S, Dasgupta S, Biswas R, Dey S, Barman A. A Study of Clinical Outcome of Precontoured Plate & Screw Fixation in Fracture Midshaft Clavicle. *Ann. Int. Med. Den. Res.* 2018; 4(4):OR11-OR14.

Source of Support: Nil, **Conflict of Interest:** None declared