

## Effect of Use of NSAID- Ibuprofen in Prolonged Therapeutic Doses on Mucosa of Lower Respiratory Tract of Mice- A Histological Study.

Sanket Dadarao Hiware<sup>1</sup>, Vijay Gujar<sup>2</sup>, Pradeep Bokariya<sup>2</sup>, AM Tarnekar<sup>3</sup>, MR Shende<sup>4</sup>, VR Wankhede<sup>5</sup>

<sup>1</sup>Assistant professor, Department of Anatomy, Sri Aurobindo Institute of Medical Sciences, Indore, India.

<sup>2</sup>Assistant professor, Department of Anatomy, Mahatma Gandhi Institute of Medical Sciences, Sewagram, India.

<sup>3</sup>Professor, Department of Anatomy, Mahatma Gandhi Institute of Medical Sciences, Sewagram, India.

<sup>4</sup>Professor and Head, Department of Anatomy, Mahatma Gandhi Institute of Medical Sciences, Sewagram, India.

<sup>5</sup>Associate Professor, Department of Anatomy, Mahatma Gandhi Institute of Medical Sciences, Sewagram, India.

Received: December 2015

Accepted: January 2016

**Copyright:** © the author(s), publisher. It is an open-access article distributed under the terms of the Creative Commons Attribution Non-Commercial License, which permits unrestricted non-commercial use, distribution, and reproduction in any medium, provided the original work is properly cited.

### ABSTRACT

**Background:** Non-steroidal anti-inflammatory drugs (NSAIDs) are a class of drugs that provides analgesic (pain-killing) and antipyretic (fever-reducing) effects and in higher doses, anti-inflammatory effects. The present case control study was performed to find out whether prolonged oral administration of a non-selective NSAID- ibuprofen in therapeutic doses produces any micro-structural changes in the mucosa of lower respiratory tract of adult Swiss albino mice. **Methods:** The adult Swiss albino mice (25 in each group) were given either 40mg/kg commercial ibuprofen suspension (experimental group) or equivalent volume of distilled water (control group) by oral route by gastric gavage method once daily for 6 weeks. Histomorphometry was performed with linear ocular micrometer scale to quantify certain histological parameters namely outer diameter, inner diameter, wall thickness and proportion of wall thickness (PWT). **Results:** Reduction in the body weight at the end of dosing period in both the groups of mice but significant weight loss in experimental group of mice. Microscopically the findings of less airy lung tissue in the experimental group were notable. Mean values of proportion of wall thickness (PWT) were compared in experimental and control group and although apparently the PWT in experimental group seemed to be increased it was not significant statistically. **Conclusion:** The present study reflects the low possibility of toxic role of ibuprofen on the lung tissue of the mice in human equivalent therapeutic doses although it is not statistically significant. Hence, although any life threatening side effect has not been noticed in the mice, its use should be judged before advocating prolonged dosage.

**Keywords:** Ibuprofen, therapeutic dose, lower respiratory tract, histology, histomorphometric study.

### INTRODUCTION

Non-steroidal anti-inflammatory drugs (NSAIDs) are a class of drugs that provides analgesic (pain-killing) and antipyretic (fever-reducing) effects and in higher doses, anti-inflammatory effects. Most of these drugs are over the counter drugs and are available in various forms such as tablets, gels, lotions, creams, injections, sprays etc. Their usage have become so common that even common man is aware about their brand names, indications and side effects related to various organ systems such as

GIT, kidney etc. Due to the rampant use of NSAIDs by people in many diseases, the side effects of various NSAIDs have been diagnosed in many cases.<sup>[1,2]</sup>

The aspirin is considered as the most notorious NSAID for its effect on GIT. The side effects of NSAIDs have been very well documented worldwide on various organs such as liver, kidney, gastro intestinal tract (GIT) etc. It causes ulceration and acidity in GIT.<sup>[3]</sup>

These side effects of NSAIDs are not due to localized action but because of their pharmacological interaction with body at cellular and metabolic level.<sup>[4]</sup> Thus one doubt raises in mind that if side effects of these drugs can occur on GIT, heart, kidney, liver etc. then why not lungs?

Exposure to aspirin or other non-steroid anti-inflammatory drugs (NSAIDs) exacerbates bronchospasms with asthma and rhinitis. The

#### Name & Address of Corresponding Author

Dr. Vijay Gujar  
Assistant professor in Anatomy,  
Mahatma Gandhi Institute of Medical Sciences,  
Sewagram,  
Wardha, India.

aspirin induced asthma is very well known side effect. It leads to 'Samter's Triad' which is a medical condition consisting of asthma, aspirin NSAID sensitivity and nasal/ethmoidal polyposis.<sup>[5]</sup> The effects are produced due to blockage of COX-1 enzyme and some other factors. So other NSAIDs which are non-selective COX inhibitors can also produce similar type of symptoms. Prevalence of cross sensitivity of acetaminophen in aspirin sensitive asthmatic subjects has been observed in high doses. Ibuprofen is a non-selective COX inhibitor NSAID having antipyretic, analgesic and anti-inflammatory properties. It can also have cross sensitivity in similar manner.<sup>[6,7]</sup>

The chemical formula of Ibuprofen is C<sub>13</sub>H<sub>18</sub>O<sub>2</sub> and chemical name is 2-(4-Isobutylphenyl) propionic acid.<sup>[8]</sup>

The human respiratory system is divided into 2 portions, namely, the conducting portion and the respiratory portion. The conducting portion is responsible for passage of air from external environment to respiratory portion of lungs during inhalation and vice versa during exhalation. It is responsible for conditioning of the inspired air by humidifying it and removing the dust particles with the help of hair in nostrils and the mucous layer on the epithelial surface. The respiratory portion is involved in the exchange of oxygen and carbon dioxide between the blood and inspired air. Besides its primary respiratory role in gaseous exchange and ventilation, a number of accessory activities are performed by the respiratory system such as production of sound (phonation) by the larynx and related other structures, odorant sampling by olfactory sensors in nasal chambers, mechanical stabilization of the thorax during mechanical exertion and various biochemical functions such as conversion of Angiotensin I to Angiotensin II (a process concerned with regulation of body's blood pressure).<sup>[9-11]</sup>

The mucosa of respiratory part includes the epithelial lining and the underlying lamina propria. The epithelium gradually decreases in thickness from pseudo stratified columnar ciliated epithelium to simple cuboidal epithelium and finally to simple squamous epithelium. Goblet cells gradually reduce in number and completely disappear in bronchioles. Goblet cells are replaced by Clara cell in bronchioles.<sup>[5,7]</sup>

The alveolar epithelium varies in thickness but extensive area of it is as little as 0.05 micron thick. The epithelium lies on the thin basal lamina which is in places fused with that of adjacent capillaries. It forms a continuous layer about 0.1 microns thick. The thickness of the capillary endothelium is 0.05 micron, so that the total barrier to diffusion between air and blood may be as little as 0.2 micron. The mean barrier thickness is 2.2 micron in the normal human lung.<sup>[12]</sup>

The present study is carried out with the principal aim of studying the histological changes in mucosa of lower respiratory tract as an effect of chronic use of NSAID-Ibuprofen in human equivalent therapeutic doses after setting a case-control study in Swiss albino mice as laboratory rodents.

## MATERIALS AND METHODS

Present case control study was performed on Swiss albino mice in order to study microscopic changes in the mucosa of lower respiratory tract as an effect of prolonged oral administration; in human equivalent therapeutic doses; of an NSAID drug-Ibuprofen.

Adult Swiss Albino mice were obtained from an authorized breeding centre. An average life span of Swiss albino mice is 2-3 years.<sup>[10]</sup> These mice were used for experimental purpose after dividing them in control and experimental sets. 25 adult mice of either sex used as control group were given distilled water and 25 adult mice of either sex used as experimental group were given drug Ibuprofen. The dose was administered daily for 6 days per week for a total of 6 weeks and then the mice were sacrificed after 1 week of completion of doses by cervical dislocation for isolating the lungs by dissection.

Ibuprofen was used in our study as it is one of the most common ingredients in single or combined preparations prescribed for prolonged medication in certain diseases. It is a non-selective prostaglandin inhibitor used for its anti-inflammatory, analgesic and antipyretic effects. Commercial Ibugesic suspension was used with distilled water as vehicle. Normal saline was used for setting perfusion.

Stains: Haematoxylin and Eosin (H and E), Alcian blue, PAS with haematoxylin and without haematoxylin and Masson's Trichrome.

Chemicals for tissue processing: 10% fresh formal saline as fixative and preservative, paraffin wax having a melting point 60-62°C for paraffin embedding, graded alcohols (70%, 90% and absolute alcohol), acid alcohol (0.5% and 1%), Chloroform, Xylene, Mayer's egg albumin and DPX mount.

Using specially devised non injurious metal canula attached to disposable insulin syringe the adult mice were given oral Ibuprofen suspension by gastric gavage method. The weight of the mouse was recorded on the electronic weighing machine and the drug dosage was calculated accordingly. The required dose of 40 µg/g for a mouse weighing 25 gram would be 1 mg. The suspension of commercial Ibugesic contains 100 mg Ibuprofen per 5 ml.

So 1 mg would be in 0.05 ml BCG syringe with a capacity of 1 ml was divided in 50 small segments, so that smallest segment measured 0.02 ml. Hence,

volume of Ibugesic suspension to be given to mouse weighing 25grams was measured upto 2.5 small segment of the syringe. In mouse of control group, similar quantity of distilled water was given as vehicle base. Suspension was well shaken before use. All the material used was kept clean and hygienic. Animals were given the drug at a fixed time every day (usually between 1-2 pm). Animals were returned to the cage only after ensuring that the drug has been well swallowed by the animal and there is no wastage of drug by spillage or reflux.

In the mucosa of lower respiratory tract, the main target area for microscopy in present study was lining epithelium. Microscopic examination was started with scanner objective (40 times magnification) to get an overview of general architecture of the lung tissue section. Then the particular area of interest was observed under low power objective (100 times magnification). The outer diameter, inner diameter, proportional wall thickness etc were measured by high power objective (400 times magnification). Proportional wall thickness refers to the proportion of wall occupied by epithelium. This parameter has been considered to avoid erroneous interpretation of consideration of epithelial height in microns.

Total 10 slides were made (each containing 3 sections) from each lung embedded in wax. As we had mounted serial sections on pre-scored glass slides and each slide had 3 sections of approximately 7  $\mu$ m thickness, we used alternate slides for H & E, PAS, Masson's trichrome and Alcian blue staining so that nearly similar object in view by one stain could be simultaneously located with remaining stains in different slides. Next 2 slides were again stained with H & E for histomorphometry. Rest 4 slides were kept unstained as reserve for any further desired staining as per the need.

#### **Following parameters were measured**

Vertical wall thickness (VWT) = Outer vertical diameter (OVD) - Inner vertical diameter (IVD)

Transverse wall thickness (TWT) = Outer transverse diameter (OTD) - Inner transverse diameter (ITD)

#### **Thus on the basis of these parameters we calculated**

- Mean outer diameter (MOD)
- Mean inner diameter (MID)
- Mean wall thickness (MWT)
- Proportion wall thickness (PWT) refers to the proportion of outer diameter occupied by wall.

The parameters of small, intermediate and large airway of control and experimental groups were compared separately. The average value of a particular parameter of both the groups was obtained. The difference in the values of two

groups was then calculated and its statistical significance was obtained. The values in both the groups were then compared with the help of histograms and pie charts.

When number of observations of a desired parameter was less than 30 the comparison was done with unpaired (student's) 't' test. Then a standard value (S) was obtained for 5% level of confidence using d.f. from t-table, which in present study was found to be 2.08. If the calculated difference between mean observed value of a parameter in control & experimental group was more than 2.08 then the change would be considered significant with P value less than 0.05 (with 95% confidence interval). When number of observations of a desired parameter was more than 30 the comparison was done with 'z' test. Here the standard cut off value is 1.96. If the calculated difference was more than 1.96, then the change in parameter would be considered significant with P value less than 0.05 (with 95% confidence interval).

## **RESULTS**

We have closely observed the Swiss albino mice while giving the dosage and also after the dosage period. We observed the general life style of the mice, their food habits and recorded their growth so as to correlate with specific microscopic observations noted at the end of experimental dosage period after sacrificing the animals.

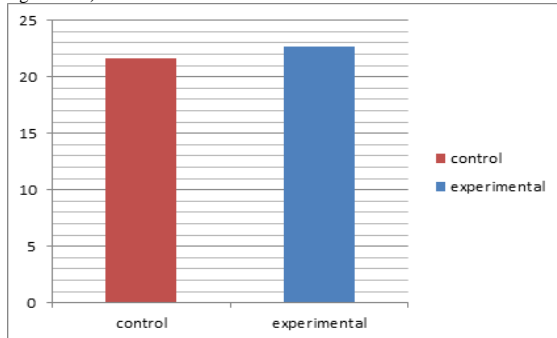
Histological sections of the lung were studied in experimental animal and critical comparison was made with the control group of animals.

The lining epithelium of large and small airways did not show any evidence of degeneration or dysplasia. Goblet cells were largely missing in airways in both groups barring the initial part of large airways. Sub-epithelial acini were also difficult to discern in two groups in H/E stained sections. To further explore the possibility of a goblet cell being missed, the Alcian blue stained lung sections were meticulously examined, but none of these revealed goblet cells or sub-epithelial acini in airways. We stained section of large intestine and mucin secreting acini with Alcian blue stain in order to cross check the correctness of our staining method. The section of large intestine and mucin secreting acini stained positive with Alcian blue stain to show goblet cells. Lamina propria was inconspicuous as it largely did not show evidence of cellular infiltration, oedema or congested vessels. The sporadic finding of cellular infiltration and even large aggregation of mononuclear cells in lungs of one or two mice appeared unworthy of reporting since it was seen in both groups.

**Table 1: Comparison of mean PWT value of small airways in both groups of mice.**

	Control group	Experimental group	z-value*	p-value
Mean of PWT	21.60 ± 3.60	22.7 ± 3.92	0.20	P > 0.05 (N.S)

\*Cut off value: 1.96 (if z-value < 1.96, then p-value > 0.05 and it is not significant.)

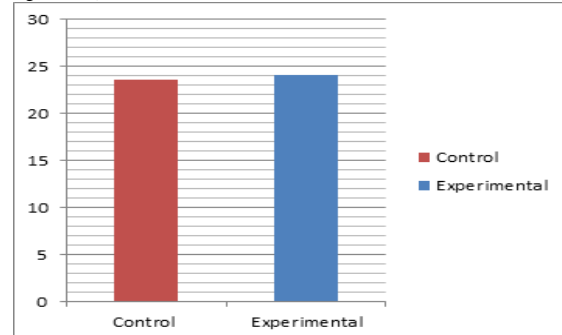


**Figure 1: Bar diagram showing the comparison of mean PWT (in %) - small airway group (A).**

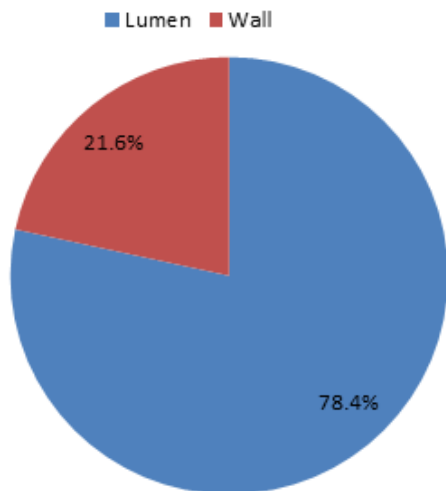
**Table 2: Comparison of mean PWT value of intermediate airways in both groups of mice.**

	Control group	Experimental group	z-value*	p-value
Mean of PWT	23.59 ± 2.14	24.05 ± 1.51	0.16	P > 0.05 (N.S)

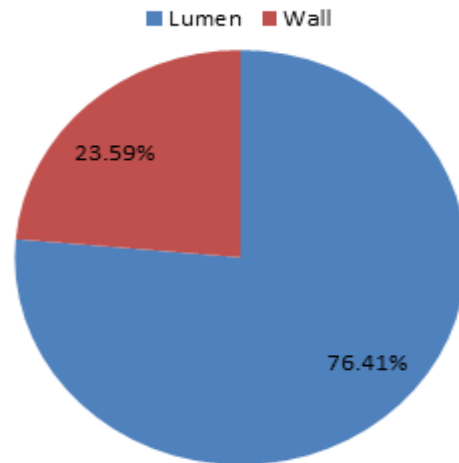
\*Cut off value: 1.96 (if z-value < 1.96, then p-value > 0.05 and it is not significant.)



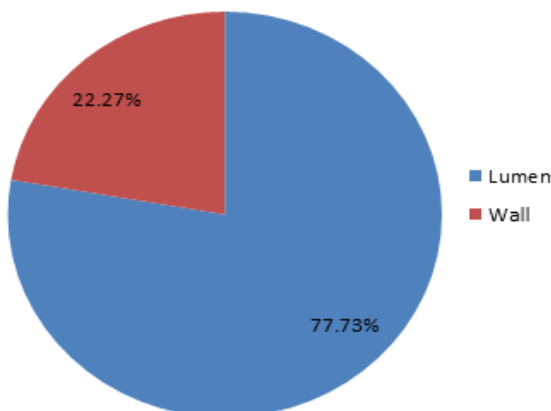
**Figure 4: Bar diagram showing the comparison of mean PWT (in %) - intermediate airway group (B).**



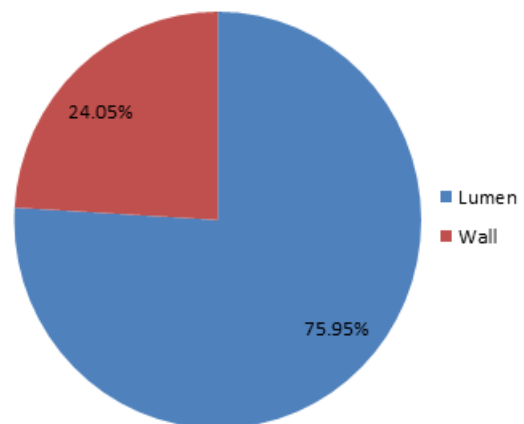
**Figure 2: Pie diagram showing the proportion of wall as compared to outer diameter in control group - (A) small airways.**



**Figure 5: Pie diagram showing the proportion of wall as compared to outer diameter in control group - in (B) intermediate diameter airways.**



**Figure 3: Pie diagram showing the proportion of wall thickness as compared to outer diameter in experimental group - (A) small airway**

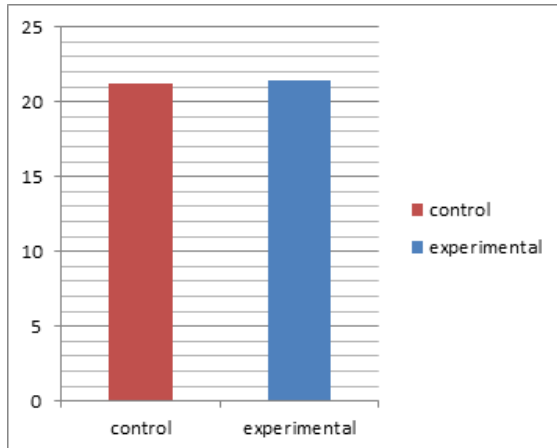


**Figure 6: Pie diagram showing the proportion of wall as compared to outer diameter in experimental group - intermediate airways.**

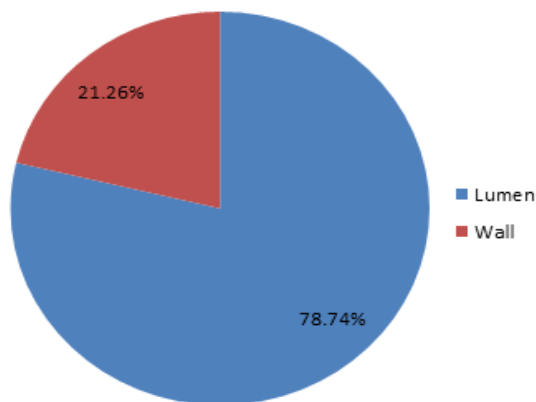
**Table 3: Comparison of mean PWT value of large airways in both groups of mice**

	Control group	Experimental group	t-value**	p-value
Mean of PWT SD	21.26 ± 1.24	21.42 ± 1.16	0.34	P > 0.05 N.S

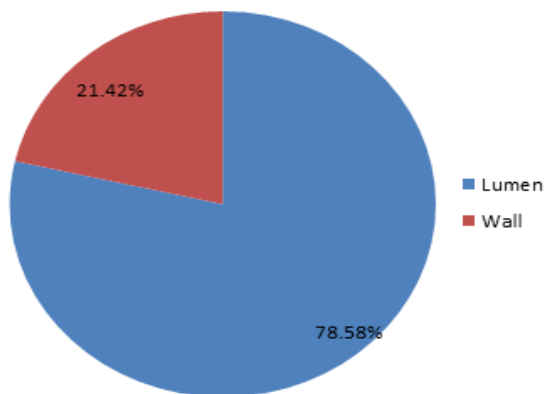
\*\*Cut off value: 2.08 (if t-value < 2.08, then p-value > 0.05 and it is not significant)



**Figure 7: Bar diagram showing the comparison of mean PWT (in %) – large airway group (C).**



**Figure 8: Pie diagram showing the proportion of wall as compared to outer diameter in control group - large airways.**



**Figure 9: Pie diagram showing the proportion of wall as compared to outer diameter in experimental group - large airways.**

## DISCUSSION

The non-steroidal anti-inflammatory drugs (NSAID) are one of the most extensively prescribed drugs all over the world. These drugs exhibit varying degree of analgesic, anti-inflammatory and antipyretic properties. The side effects of NSAIDs on various organs such as gastro intestinal tract and kidney are very well documented and physicians all over the world prescribing these drugs are well aware of these side effects of NSAIDs. There are equally well known side effects of NSAIDs on other organs such as liver, brain, lung etc which are clinically documented. The exacerbation of bronchial asthma by aspirin and some other NSAIDs has been frequently reported.<sup>[1,8,13]</sup>

So far aspirin and indomethacin are amongst the most notorious NSAIDs as far as the causation of side effects, including those on lungs, is concerned. There is paucity of data documenting the effect of ibuprofen on lungs in published literature. We considered a propionic acid derivative- ibuprofen, as a representative of non-selective NSAID as it is one of the most commonly used drug either single or in combination for prolonged pain relief medications. The reason behind consideration of ibuprofen from amongst other commonly prescribed NSAIDs in present study was the curiosity to know whether ibuprofen, so far considered as a safe NSAID for prolonged medication, produces any micro-structural changes in the mucosa of lower respiratory tract of mice when given in human equivalent therapeutic doses. The reason behind targeting the mucosa of lower respiratory tract for present study was the curiosity to know if there is any histological alteration in the mucosa of lower respiratory tract from normal (control group) in response to a prolonged dosage of NSAID given by oral route, such as ibuprofen in present case.

It is unwise to use human volunteers for histological assessment of toxic potential of a drug. Further, the choice of certain animal species for experimentation has to have a justifiable reason due to the ethical restraints. Therefore the small mammalian group was most suited in our study for carrying out an in vivo study. The results of this study could then be implicated in humans. Thus we selected the Swiss albino mice as the animal species for present study.

We have administered ibuprofen by oral route to the mice. Rainsford and Menozzi et al have also given oral NSAIDs in their experimentation.<sup>[14,15]</sup> Elliott et al,<sup>[16]</sup> have used oral, intra-peritoneal as well as intravenous route of NSAID drug administration in different animals. Whenever the prolonged therapeutic treatment is needed, the physicians prefer to prescribe NSAIDs by oral route. We anticipated that the effect of oral dose of

ibuprofen would be representative of side effects, if any, of orally administered NSAIDs on lungs. We also wanted to avoid the toxic effect that can be incurred by parenteral route of administration as the Swiss albino mice are very small species.

Researchers have administered different dosages of NSAIDs for different duration for different purposes.<sup>[6,9,11]</sup> Elliott et al,<sup>[16]</sup> in their experimentation administered ibuprofen as a single dose of 1600mg and 1000mg/kg in two groups of mice. In other experimentation they used 135, 270 and 530 mg/kg single doses by intravenous route. The researchers have used variable duration of lung exposure for NSAIDs. In case of Swiss albino mice we have considered 6 weeks dose duration to be nearly equivalent to lifelong medication. Dose duration of present study matches with researchers like Elliott et al,<sup>[16]</sup> 40mg/kg/day dose in present study is quiet low as compared to drug dosage used by other researchers, but we considered this drug dose as it is a human equivalent ibuprofen dosage rather than a toxic dose.

The animals can be sacrificed by various methods like cervical dislocation, lethal injection of ketamine, over dose of ether, blow on the head or decapitation. In our study we sacrificed mice by cervical dislocation in non-sedated animals. This causes painless instant death of mice. Ettarh and Carr and Somasundaram have used the same method as ours.<sup>[17,18]</sup>

We observed gradual loss of weight in both group of animals during the 6 weeks of experimentation. We found that weight loss was significantly more in experimental group of animals when initial weight was compared with the final weights at the time of sacrifice. Dudkiewicz,<sup>[19]</sup> also reported the loss of weight in experimental group of animals on administration of NSAID. They justified that it was due to disturbances in intestinal motor function which could have led to malabsorption syndrome.

The apparent reduction in luminal diameters of some airways in experimental set of present study could possibly be due to increased tone of smooth musculature of airway which could also result in stasis of air in distal part of such airways and then lead to reduction of volume of alveoli as well. Comparing the diameter in the two groups of animals would be unwise. Since the data to be compared would be incomparable unless a standard gauge is used. So to obtain a unified comparable value in 2 groups of airways we used percent figures rather than actually measured figures in microns. Selection criteria may restrict inclusion of similar sizes or types of airways in two groups and critical comparison may not be possible on airways of similar diameter in two groups because structural and functional status of airway may not be same in spite of same diameter. To substantiate the fact, we utilized a morphometric parameter which was deduced from observed parameter of

wall thickness and outer diameter- the proportion of wall thickness (PWT) as seen in master chart. This gave us a figure in % about the thickness of wall with respect to outer diameter. This parameter did not differ much by alteration in size of airway but was largely dependent on a change in proportion of wall and lumen in an airway. On comparison of the PWT in control and experimental groups it was revealed that although there is an increase in PWT in all 3 experimental groups – small, intermediate and large airways, it is not statistically significant.

In absence of the studies carried out with similar set up, the present study reflects the low possibility of toxic role of ibuprofen in the lung tissue of the mice in human equivalent therapeutic doses, though not so severe to cause any life threatening disability in the experimental mice. Hence its use should be judged before advocating prolonged dosage.

## CONCLUSION

- 1) Reduction in the body weight at the end of dosing period in both the groups of mice but significant weight loss in experimental group of mice.
- 2) There was no gross change in the appearance of the lung in either group.
- 3) Microscopically the findings of less airy lung tissue in the experimental group were notable.
- 4) Comparison of mean values of proportion of wall thickness (PWT) in experimental and control group revealed that the PWT is slightly increased in small, intermediate and large airway of experimental groups of mice although the comparative deviation in PWT is not statistically significant.

## REFERENCES

1. Antonicelli L, Tagliabracci A. Asthma death induced by ibuprofen. *Monaldi Arch Chest Dis.* 1995;50(4):276-8
2. Arab MR, Mirzaei R, Karimi M, Mashhadi R. The study of Histological Effects of Solder fumes in Rat Lungs. *Irani Journal of Basic Medical Sciences.* 2010;13(3):63-68.
3. Ayres JG, Flemming DM, Whittington RM. Asthma death due to ibuprofen. *Lancet.* 1987;1(8541):1082
4. Bannister L. Respiratory System. IN Gray's Anatomy The Anatomical Basis of Medicine And Surgery. Edt. Williams PL, Bannister LH, Berry MM, Collins P, Dyson M, Dussek JE and Ferguson MWJ; Churchill Livingstone Publ.) 38th Edition 2000: pp 1627- 1682.
5. Bayomy NA, Abd-Elmagyed EF and Tawfik SM. Effect of Leflunomide (Avara) Drug on the lung of Adult Male Albino Rats: A Histological and Immunohistochemical Study. *Egypt J. Histol.* 2008;31(2):278-289.
6. Bessone F. Non-steroidal anti-inflammatory drugs: What is the actual risk of liver damage? *World J Gastroenterol.* 2010;16(45):5651-5661.
7. Bhala N, Emberson J, Merhi A, Abramson S, Arber N, Baron JA et al. Vascular and upper gastrointestinal effects on non-steroidal anti-inflammatory drugs: meta-analyses of

- individual participant data from randomized trials. *Lancet*. 2013;382(9894):769-79.
8. Bulan O. The effects of propylthiouracil on small intestine of mice: a light and electron microscobical study. *IUFS J Biol* 2008; 67(2): 129-134.
  9. Burke A, Smyth E, FitzGerald G. Analgesic- antipyretic and antiinflammatory agents; pharmacotherapy of gout. In: Bruton L, Lazo J, Parker K editor, Goodman & Gilman`s The Pharmacological Basis of Therapeutics, 11th ed: McGraw Hill publication;2006.p. 671-716.
  10. ChatterjeeTK.The laboratory mouse. In: Handbook of Laboratory mice and rats,1st edition. Calcutta: Publ. Chatterjee K. K.; 1993. p.3-12.
  11. Cioli V, Putzolu S, Rossi V, ScorzaBarcellona P, Corradino C. The role of direct tissue contact in the production of gastrointestinal ulcers by anti-inflammatory drugs in rats. *Toxicology and Applied Pharmacology* 1979; 50(2): 283-289.
  12. Cowburn AS, Sladek K, Soja J, Adamek L, Nizankowska E, Szczeklik A et al. Overexpression of leulotriene C4 synthase in bronchial biopsies from patients with aspirin-tolerant asthma. *J Clin Invest*. 1998; 101(4): 834-46
  13. Debley JS, Carter ER, Gibson RL, Rosenfeld M, Redding GJ. The prevalence of ibuprofen-sensitive asthma in children: a randomized controlled bronchoprovocation challenge study. *J pediatr*. 2005; 147(2): 233-8
  14. Rainsford KD. Anti-inflammatory drugs in the 21st century. *SubcellBiochem* 2007; 42: 3-27.
  15. Menozzi A, Pozzoli C, Poli E, Dacasto M, Giantin M, Lopparelli RM, et al. Effects of nonselective and selective cyclooxygenase inhibitors on small intestinal motility in the horse. *Res Vet Sci* 2009; 86(1): 129-135.
  16. Elliott GA, Purmalis A, VanderMeer DA, Denlinger RH. The propionic acids. Gastrointestinal toxicity in various species. *ToxicolPathol* 1988; 16 (2): 245-250.
  17. Ettarh RR and Carr KE. Morphometric analysis of the small intestinal epithelium in the indomethacin-treated mouse. *J Anat* 1996; 189: 51-56.
  18. Somasundaram S, Rafi S, Hayllar J, Sigthorsson G, Jacob M, Price AB, et al. Mitochondrial damage: a possible mechanism of the "topical" phase of NSAID induced injury to the rat intestine. *Gut* 1997; 41(3): 344-353.
  19. Dudkiewicz J. Ibuprofen-induced gastrointestinal changes. *ActaPhysiol Pol* 1981; 32(6): 693-701.

**How to cite this article:** Hiware SD, Gujar V, Bokariya P, Tarnekar AM, Shende MR, Wankhede VR. Effect of Use of NSAID- Ibuprofen in Prolonged Therapeutic Doses on Mucosa of Lower Respiratory Tract of Mice- A Histological Study. *Ann. Int. Med. Den. Res.* 2018; 4(4):AT01-AT07.

**Source of Support:** Nil, **Conflict of Interest:** None declared